

## CASE REPORT

DOI: 10.37047/jos.2023-96095

# Management of Nasal Lobular Capillary Hemangioma with Sunitib

<sup>a</sup> Ali ALKAN<sup>a</sup>, <sup>b</sup> Bilge Can UYAR<sup>b</sup>, <sup>b</sup> Ece Dilan BOZKURT<sup>b</sup>, <sup>b</sup> Resmiye Irmak YÜZÜGÜLDÜ<sup>c</sup>,  
<sup>d</sup> Erdoğan ÖZGÜR<sup>d</sup>, <sup>a</sup> Sait KİTAPLI<sup>a</sup>, <sup>a</sup> Özgür TANRIVERDİ<sup>a</sup>

<sup>a</sup>Division of Medical Oncology, Muğla Sıtkı Koçman University Faculty of Medicine, Muğla, Türkiye

<sup>b</sup>Department of Internal Medicine, Muğla Sıtkı Koçman University Faculty of Medicine, Muğla, Türkiye

<sup>c</sup>Department of Pathology, Muğla Sıtkı Koçman University Faculty of Medicine, Muğla, Türkiye

<sup>d</sup>Department of Otorhinolaryngology, Head and Neck Surgery, Muğla Sıtkı Koçman University Faculty of Medicine, Muğla, Türkiye

**ABSTRACT** Lobular capillary hemangioma (LCH) or pyogenic granuloma is a rare benign lesion originating from the nasal cavity. We present a case of nasal LCH successfully palliated with sunitinib. A 65-year-old male patient was hospitalized because of swelling and hyperemia in the periorbital region for 3 months. A month before admission, episodic epistaxis occurred. Magnetic resonance imaging showed a 35×62×63-mm solid mass filling the right half of the nasal cavity. The biopsy showed LCH, and the patient was diagnosed with metastatic renal cell carcinoma (RCC). The tumor board discussed a strategy that can primarily treat metastatic RCC and symptomatic palliation of LCH. Moreover, sunitinib treatment provided palliation of symptoms related to nasal LCH. He reported that swelling, pain, and epistaxis disappeared during the treatment.

**Keywords:** Lobular capillary hemangioma; renal cell carcinoma; sunitinib; vascular endothelial growth factor

Renal cell carcinoma (RCC) is the most common malignancy of the kidney and highly vascular neoplasia that is provided by the vascular endothelial growth factor (VEGF) pathway.<sup>1</sup> Approximately 30% of patients present with advanced or metastatic disease, and systemic therapies are the mainstay treatment strategy in these scenarios. The most effective first-line options are anti-VEGF, immune checkpoint inhibitors, and their combinations. Sunitinib, pazopanib, lenvatinib, cabozantinib, and axitinib have been tested as first-line treatment either as monotherapy or in combination with pembrolizumab or nivolumab.<sup>2</sup> Additionally, these drugs are actively used and have changed the current practice owing to better overall survival rates.

Lobular capillary hemangioma (LCH) or pyogenic granuloma is a benign lesion resulting from the vascular proliferation of endothelial cells. It is characterized by limited capillary vessels acquiring a lobular structure. Similar to hemangiomas, positive

angiogenesis regulators are present, and VEGF-A signaling is crucial to their development.<sup>3</sup> However, the etiology is unknown.<sup>4</sup> It has a female predominance. LCH generally affects the mucous membranes of the skin and oral cavity, and the nasal cavity can also be affected. Nasal cavity LCH mostly originates from the nasal septum, nasal vestibule, and inferior turbinate. Generally, the lesions range between 1 and 8 cm. Patients generally present with epistaxis, nasal obstructive symptoms, and rhinorrhea, and imaging and histopathological evaluation confirm the diagnosis.<sup>5,6</sup> Moreover, the main treatment of LCH is surgical resection, classical local excision, or endoscopic excisional surgery. For unresectable diseases, cryotherapy, laser ablation, intralesional or systemic corticosteroids, and interferon are recommended as alternative treatment methods.<sup>7,8</sup> The use of anti-VEGF agents could be effective due to the high VEGF expression of LCH. For example, bevacizumab is effective when used intralesionally.<sup>9,10</sup> The

**Correspondence:** Ali ALKAN

Division of Medical Oncology, Muğla Sıtkı Koçman University Faculty of Medicine, Muğla, Türkiye

**E-mail:** alkanali@gmail.com

Peer review under responsibility of Journal of Oncological Sciences.

**Received:** 14 Feb 2023

**Accepted:** 04 May 2023

**Available online:** 25 May 2023

2452-3364 / Copyright © 2023 by Turkish Society of Medical Oncology. This is an open access article under the CC BY-NC-ND license (<http://creativecommons.org/licenses/by-nc-nd/4.0/>).



efficacy of systemic anti-VEGF drugs has not been tested in treating LCH. Here, we present a case of nasal LCH successfully palliated with sunitinib.

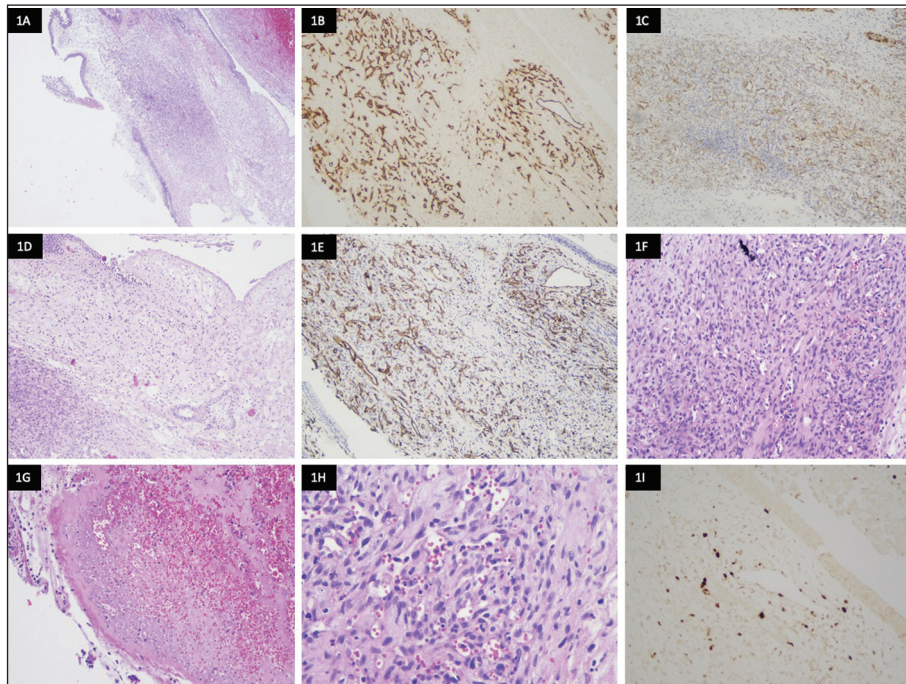
"An informed consent was provided to share the clinical data and the images of the patient." should be added.

## CASE REPORT

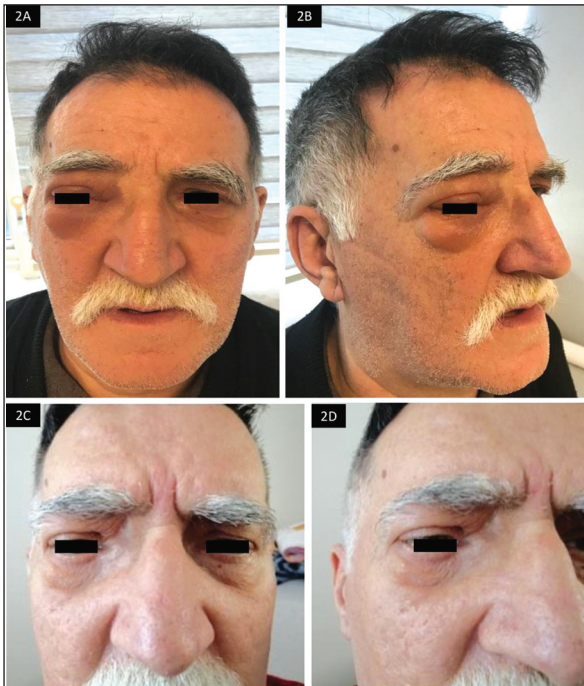
A 65-year-old male patient was hospitalized because of swelling and hyperemia in the periorbital region for 3 months. Episodic epistaxis also occurred a month prior. His hypertension is well-controlled using 2 anti-hypertensive drugs. Physical examination revealed a soft tissue mass at the upper superomedial of the right eye, which occluded the right nasal cavity. On maxillofacial imaging with contrast-enhanced magnetic resonance imaging, the lobule-contoured solid mass measuring 35×62×63 mm in the widest part filled the right half of the nasal cavity, which extended to the superior, middle, and inferior meatus. In the staging work-up for the differential di-

agnosis of malignancy, computerized tomography revealed multiple metastatic lesions in both lungs and a heterogeneous mass of 98×90 mm originating from the right renal cortex. The incisional biopsy of the nasal mass showed vascular neoplasia with positive staining with CD31, CD34, and actin in immunohistochemistry. Ki-67 proliferation activity was 15%-20%, and the diagnosis of LCH was confirmed (Figure 1).

Because of the metastatic lesion and large solitary renal mass, renal biopsy was performed, which showed RCC. The management of metastatic RCC and unresectable LCH was discussed in the head and neck tumor board. Subsequently, a strategy to primarily treat RCC and symptomatic treatment of LCH was planned. Sunitinib at 50 mg daily (2 weeks on/1 week off) was started for metastatic RCC. In the 3-month follow-up, partial regression was observed in the primary and metastatic disease. The patient reported palliation of the symptoms related to nasal LCH (Figure 2A/B). Additionally, swelling and dis-



**FIGURE 1:** Capillaries with a lobular structure under the respiratory epithelium (4x) (1A), CD34 (positive for endothelial cells)-organized capillaries around the feeder vessel (10x) (1B), smooth muscle actin positive in the pericytic cell population (10x) (1C), edematous and fibromyxoid stroma (10x) (1D), CD31 (positive for endothelial cells) (x10) (1E), some of the capillaries have no compressible and identifiable lumen (20x) (1F), areas of necrosis and hemorrhage (x20) (1G), endothelial cells I uniform structure, without pleomorphism (x40) (1H), ki67 15% (x20) (1I).



**FIGURE 2:** The frontal (2A) and lateral aspect (2B) of the patient demonstrating the periorbital swelling on the right eye. The symptomatic and clinical improvement of the lobular capillary hemangioma (2C-2D).

coloration of the right upper eye regressed, as well as the disappearance of swelling, pain, and epistaxis during treatment (Figure 2C/D). However, symptoms recurred during the 1-week pauses. Symptom fluctuations on the on/off days continued until the clinical visit. A stable lesion in the nasal cavity was observed in the imaging during the second month of treatment. Thus, sunitinib was continued for 10 months until progression. Furthermore, nivolumab 3 mg/kg was initiated as second-line treatment. However, the symptoms of LCH exacerbated during the second cycle of nivolumab, and the patient was re-challenged with sunitinib 25 mg daily continuously. Consequently, LCH symptoms disappeared. He had Grade II malaise, Grade II nausea, and skin toxicity without any Grade III/IV toxicity. The patient was treated with sunitinib and nivolumab for 6 months without progression. Moreover, LCH symptoms did not recur.

## DISCUSSION

The efficacy of anti-VEGF drugs in treating RCC has been well-established in the last decade. However,

data regarding their impact on benign lesions are limited. Hemangiomas are a group of benign tumors wherein VEGF-A is essential for hemangiogenesis and its maintenance.<sup>3</sup> Here, we documented the clinical improvement and symptomatic relief of nasal LCH in a patient with metastatic RCC treated with sunitinib. In the literature, bevacizumab also showed similar effective symptomatic improvement. Bevacizumab is a humanized monoclonal antibody that binds VEGF-A, an important signaling molecule promoting angiogenesis. Kinzinger et al. reported a case of sinonasal hemangioma treated with intranasal bevacizumab, which provided both complete symptomatic relief and decreased tumor size.<sup>9</sup> In addition, Bouzouba et al. showed the impact of intranasal bevacizumab in childhood palpebral hemangioma.<sup>10</sup>

Sunitinib malate is a tyrosine kinase inhibitor (TKI), which blocks VEGFR-1/2, platelet-derived growth factor receptors, FMS-like tyrosine kinase III, and receptor tyrosine kinase C-KIT.<sup>11</sup> In-vivo studies reported reduced endothelial cell growth through accumulation in the sub-G1 phase and decreased hemangioma cell migration. The study suggested that sunitinib could be used in treating hemangiomas.<sup>12</sup> However, no data are available regarding anti-VEGF TKIs in hemangioma treatment. Our experience is unique because sunitinib showed efficacy in the palliative management of LCH. Although all of immune checkpoint inhibitor plus TKI combination studies have been conducted with TKIs other than sunitinib, we continued using sunitinib because it resulted in symptomatic improvement. In addition, the patient was treated with sunitinib 25 mg due to toxicity concerns. However, low-dose sunitinib provided effective palliation without Grade III-IV toxicity.

LCH is a rare entity originating from the nasal cavity. Our case provided important clues on the use of sunitinib for the palliative management of LCH. Therefore, this incidental finding could provide a new perspective on the treatment of surgical or medical inoperable LCH cases.

### Source of Finance

*During this study, no financial or spiritual support was received neither from any pharmaceutical company that has a direct con-*

nection with the research subject, nor from a company that provides or produces medical instruments and materials which may negatively affect the evaluation process of this study.

### Conflict of Interest

No conflicts of interest between the authors and / or family members of the scientific and medical committee members or members of the potential conflicts of interest, counseling, expertise, working conditions, share holding and similar situations in any firm.

### Authorship Contributions

**Idea/Concept:** Ali Alkan; **Design:** Ali Alkan, Bilge Can Uyar; **Control/Supervision:** Ali Alkan, Sait Kitaplı, Özgür Tanrıverdi; **Data Collection and/or Processing:** Ali Alkan, Bilge Can Uyar, Ece Dilan Bozkurt; **Analysis and/or Interpretation:** Ali Alkan, Bilge Can Uyar, Ece Dilan Bozkurt; **Literature Review:** Ali Alkan, Bilge Can Uyar, Sait Kitaplı; **Writing the Article:** Ali Alkan, Bilge Can Uyar; **Critical Review:** Ali Alkan, Özgür Tanrıverdi; **References and Fundings:** Ali Alkan, Bilge Can Uyar, Ece Dilan Bozkurt; **Materials:** Ali Alkan, Resmiye Irmak Yüzügüldü, Erdoğan Özgür.

## REFERENCES

- Hsieh JJ, Purdue MP, Signoretti S, et al. Renal cell carcinoma. Nat Rev Dis Primers. Mar 2017;3:17009. [Crossref] [PubMed] [PMC]
- Bosma NA, Warkentin MT, Gan CL, et al. Efficacy and safety of first-line systemic therapy for metastatic renal cell carcinoma: a systematic review and network meta-analysis. Eur Urol Open Sci. Jan 2022;37:14-26. [Crossref] [PubMed] [PMC]
- Park M, Jung HL, Shim YJ, et al. Serum cytokine profiles in infants with infantile hemangiomas on oral propranolol treatment: VEGF and bFGF, potential biomarkers predicting clinical outcomes. Pediatr Res. 2020;88(5):749-755. [Crossref] [PubMed]
- Chi TH, Yuan CH, Chien ST. Lobular capillary hemangioma of the nasal cavity: a retrospective study of 15 cases in taiwan. Balkan Med J. 2014;31(1):69-71. [Crossref] [PubMed] [PMC]
- Puxeddu R, Berlucchi M, Ledda GP, Parodo G, Farina D, Nicolai P. Lobular capillary hemangioma of the nasal cavity: A retrospective study on 40 patients. Am J Rhinol. 2006;20(4):480-484. [Crossref] [PubMed]
- Nair S, Bahal A, Bhadauria RS. Lobular capillary hemangioma of nasal cavity. Med J Armed Forces India. 2008;64(3):270-271. [Crossref] [PubMed] [PMC]
- Smith SC, Patel RM, Lucas DR, McHugh JB. Sinonasal lobular capillary hemangioma: a clinicopathologic study of 34 cases characterizing potential for local recurrence. Head Neck Pathol. 2013;7(2):129-134. [Crossref] [PubMed] [PMC]
- MacArthur CJ, Senders CW, Katz J. The use of interferon alfa-2a for life-threatening hemangiomas. Arch Otolaryngol Head Neck Surg. 1995;121(6):690-693. [Crossref] [PubMed]
- Kinzing MR, Strong EB, Bernard J, Steele TO. Intralesional bevacizumab for the treatment of recurrent sinonasal hemangioma. Ann Otol Rhinol Laryngol. 2018;127(12):969-973. [Crossref] [PubMed]
- Bouzouba T, Chabbar I, Tamym B, et al. Intra-lesional injection of anti-VEGF in the management of childhood palpebral hemangioma. IOSR Journal of Dental and Medical Sciences. 2020;19(2):26-32. [Link]
- Haas B, Weber-Lassalle K, Frötschl R, Eckstein N. Is sunitinib a narrow therapeutic index drug? - A systematic review and in vitro toxicology-analysis of Sunitinib vs. Imatinib in cells from different tissues. Regul Toxicol Pharmacol. Jun 2016;77:25-34. [Crossref] [PubMed]
- Scholtz W, Mabeta P. Sunitinib malate inhibits hemangioma cell growth and migration by suppressing focal adhesion kinase signaling. J Appl Biomed. 2020;18(4):143-151. [Crossref] [PubMed]