



Application of autologous serum eye drops after pterygium surgery: a prospective study

Sabahattin Sul¹ · Safak Korkmaz² · Goksu Alacamli¹ · Pelin Ozyol¹ · Erhan Ozyol¹

Received: 24 February 2018 / Revised: 25 June 2018 / Accepted: 12 July 2018 / Published online: 18 July 2018
© Springer-Verlag GmbH Germany, part of Springer Nature 2018

Abstract

Purpose The study aims to determine the effect of 50% autologous serum drops (ASD) on corneal healing and patient comfort following pterygium surgery.

Methods Fifty eyes of 50 patients who underwent pterygium excision combined with autologous conjunctival graft were included in this prospective randomized study: in 25 eyes, 50% ASD. In the remaining 25 eyes, conventional artificial tears (CAT) were applied postoperatively until corneal epithelium had completely epithelialized. Corneal epithelium healing speed, visual analog scale (VAS) for postoperative pain assessment, conjunctival inflammation, and recurrences were evaluated. Patients were followed up for 6 months.

Results Mean corneal epithelium closure time was 3.16 ± 0.37 days (range 3 and 4 days) in ASD group and 4.96 ± 0.84 days in CAT group (range 4 and 6 days), and the difference was statistically significant ($p < 0.001$). VAS scores were significantly lower in ASD group than CAT group in the first 5 days after surgery. In 9 of 50 eyes, moderate conjunctival inflammation continued 1 month: 4 (16%) in ASD group and 5 (20%) in CAT group ($p = 0.713$). In total, pterygium recurrence was seen in 5 (10%) eyes: 2 eyes (8%) in ASD group and 3 eyes (12%) in CAT group ($p = 0.637$).

Conclusion ASD accelerated corneal epithelial healing following pterygium surgery. ASD group had lesser pain that was seen to be related with accelerated corneal epithelial healing.

Keywords Pterygium surgery · Corneal epithelial defect · Patient discomfort · Autologous serum drops

Introduction

Pterygium is a common ocular surface disorder characterized by a fibrovascular growth of the bulbar conjunctiva onto the cornea. The main treatment of pterygium is surgical excision. Surgery is usually performed under subconjunctival anesthesia [1]. Patients would experience pain and ocular discomfort after elimination of the effect of anesthesia (general or subconjunctival).

Non-steroidal anti-inflammatory drugs, topical anesthetics, and opioids have been used to relieve pain and discomfort after surgery [2–5]. Delayed epithelial healing was also associated with postoperative pain and discomfort [6]. Soft contact

lenses were used to accelerate corneal re-epithelization after ocular surgery [7].

Autologous serum has been used widely to treat dry eye disease and persistent epithelial defects [8, 9]. Furthermore, autologous serum drops have been used to promote epithelial healing following penetrating keratoplasty, vitreoretinal surgery, and refractive surgery [10–12].

In the literature, there is no data that evaluates the effect of autologous serum after pterygium surgery on acceleration of epithelial healing and decreasing the patient pain and discomfort after surgery. In this study, we aimed to determine the effect of autologous serum on epithelial healing and patient discomfort after pterygium surgery.

✉ Sabahattin Sul
drsulgoz@gmail.com

¹ Department of Ophthalmology, Muğla Sıtkı Koçman University, 48000 Muğla, Turkey

² Department of Ophthalmology, Düzce State Hospital, Düzce, Turkey

Materials and methods

Fifty eyes of 50 patients who underwent pterygium excision combined with conjunctival autograft were included in this prospective study. Written informed consent was obtained

from all patients. The study was approved by the Ethics Committee of Muğla Sıtkı Koçman University Faculty of Medicine (registration no. 0806201711/1), and the tenets of Declaration of Helsinki were followed throughout the study.

Recorded information included preoperative and postoperative medical and ocular history, snellen visual acuity, applanation tonometry, slit-lamp examination, and fundoscopy.

Anesthesia of the conjunctiva and cornea was induced by topical application of 0.5% alcaine and supplemented by 0.5 mL of jetocaine injected subconjunctivally with a 25-gauge needle, which was inserted into the body of the pterygium. The head of the pterygium was dissected from the cornea with crescent knife. The body of the pterygium, including the adjacent Tenon's capsule, and a 0.5- to 1-mm strip of border free of pterygium were excised from the surrounding conjunctiva with Westcott scissors, leaving a bare sclera. Minimal cautery was applied to bleeding vessels. Of the jetocaine, 0.5 mL was injected under superior conjunctiva to separate the conjunctiva from Tenon's capsule. A conjunctival graft matching the bare sclera was harvested from the superior bulbar conjunctiva to the limbus. The free graft was placed in the appropriate orientation onto the scleral bed and sutured with 10/0 nylon interrupted sutures sufficiently.

The patients who have been included in this study had no systemic (e.g., diabetes mellitus) or ocular diseases which can delay the corneal epithelium healing. In addition, patients who had similar pterygium size and postoperative corneal epithelium defect areas following surgery were included in this study. Of the patients, 25 were randomly assigned to receive 50% autologous serum drops (ASD group) and the remaining conventional artificial tears (CAT group) (carboxymethylcellulose 5%, Refresh tears®, Allergan) following surgery. The odd-numbered patients received ASD while even-numbered patients received CAT. Patients used 50% ASD or artificial tears eight times daily until corneal epithelium had completely epithelialized. Patients in the ASD group were not allowed to use additional artificial tears. Corneal epithelium healing was followed with fluoresceine staining and anterior segment photography. Each patient was treated with topical steroids (dexamethasone 1%, Maxidex, Alcon Lab.) four times daily after surgery. The steroid treatment was tapered off and discontinued after 1 month. Topical antibiotics were used until the wound had completely epithelialized. All sutures were removed at the end of first week. Preoperative pterygium sizes, postoperative corneal epithelium defect areas, corneal epithelium healing speed, visual analog scale (VAS) for postoperative pain assessment, conjunctival inflammation, and recurrences were evaluated. Preoperative pterygium sizes and immediate postoperative corneal epithelium defect areas (fluoresceine stained areas) were marked in anterior segment photos by the first author and measured by an engineer by using the AutoCAD (AutoCAD 2013, Autodesk, CA,USA) program whether the groups were comparable. Ocular pain

was assessed using a VAS (0–10) as shown previously [13]. A score of 0 represented no pain and 10 represented worst pain. Conjunctival inflammation was defined as vascular injection and hyperemia in the graft and host-conjunctival area. Conjunctival inflammation was graded as “grade 0 = no inflammation, grade 1 = mild inflammation, grade 2 = moderate inflammation, and grade 3 = severe inflammation” as previously described by Kheirkah et al. [14]. Recurrence was defined as any fibrovascular growth onto the cornea beyond the limbus. All of the patients were examined daily at the same time (morning) for 1 week and 1, 2, 3, and 6 months after surgery and epithelial defects were marked by the same examiner (first author) who was blinded to the treatment groups.

Preparation of autologous serum eye drop

A whole blood (20 mL) was taken from peripheral vein with vacutainer and allowed to clot at room temperature for 1 h. The blood was then centrifuged at 3000g for 10 min. Autologous serum was carefully prepared under laminar air-flow cabinet, and diluted with 1:2 with artificial tear (Refresh tears®) in a sterile bottle. Patients were asked to keep the bottles refrigerated at about 4 °C.

Statistical analysis was performed using SPSS 16.0 software (SPSS, Chicago, IL). The chi-squared (χ^2) test was performed for categorical data and Mann-Whitney *U* test for continuous data. A *p* value of less than 0.05 was considered to indicate statistical significance.

Results

The mean age was 48.9 ± 11.7 years in ASD group (range 29 and 65 years) and 50.2 ± 11.9 in CAT group (range 28 and 65 years). There were 11 (44%) men and 14 (56%) women in the ASD group and 13 (52%) men and 12 (48%) women in the CAT group. Mean pterygium size was similar between two groups before the surgeries [ASD 16.8 ± 0.33 mm² (range 16.5–18), CAT 16.7 ± 0.46 mm² (range 16.3–18.2), *p* = 0.7]. Mean corneal epithelium closure time was significantly lower in ASD group than CAT group (Table 1). In ASD group, corneal epithelium was closed in 3 days in 21 (84%) eyes and 4 days in 4 (16%) eyes (Fig. 1a–e). In CAT group, corneal epithelium was closed in 4 days in 9 (36%) eyes, 5 days in 8 (32%) eyes, and 6 days in 8 (36%) eyes (Fig. 1f–k). Mean immediate postoperative corneal epithelium defect areas were comparable between two groups [ASD group 16.4 ± 0.29 mm² (range 16–17) and CAT group 16.48 ± 0.37 mm² (range 16–17), *p* = 0.6]. VAS scores were significantly lower in ASD group than CAT group in the first 5 days after surgery (Table 1). In 9 of 50 eyes, a moderate conjunctival inflammation continued for 1 month: 4 (16%) in ASD group and 5 (20%) in CAT group (*p* = 0.7). In total, pterygium recurrence

Table 1 Mean epithelial closure time, mean immediate postoperative corneal epithelium defect area, and visual analog scale of autologous serum drop and conventional artificial tear groups

	ASD	CAT	p
Mean epithelial closure time (days)	3.16 ± 0.37 (range 3–4)	4.96 ± 0.84 (range 4–6)	< 0.001
Mean immediate postoperative corneal epithelium defect area (mm ²)	16.4 ± 0.29 (range 16–17)	16.48 ± 0.37 (range 16–17)	0.6
VAS day 1	5.5 ± 0.9	7.1 ± 1	< 0.001
VAS day 2	3.3 ± 0.7	5.2 ± 0.9	< 0.001
VAS day 3	1 ± 0.7	3.2 ± 0.7	< 0.001
VAS day 4	0.4 ± 0.5	1.6 ± 0.6	< 0.001
VAS day 5	0.16 ± 0.3	0.72 ± 0.5	< 0.001

VAS visual analog scale, ASD autologous serum drop, CAT conventional artificial tear

was seen in 5 (10%) eyes: 2 eyes (8%) in ASD group and 3 eyes (12%) in CAT group ($p = 0.6$).

Discussion

The conjunctival autograft technique has been used to treat primary pterygia successfully. However, recurrence of pterygium and ocular pain are the main concerns following pterygium surgery. In the literature, the recurrence rate of this technique is 2–39% [15, 16]. Our overall recurrence rate was 10% and was consistent with the literature.

Ocular surface inflammation may persist and trigger the recurrence of pterygium [14]. ASD may worsen the ocular surface inflammation besides its beneficial effects on the healing of the ocular surface. Because ingredients of serum such as leukocytes, pro-inflammatory cytokines (IL-17 and IFN- γ), and matrix metalloproteinase may worsen the ocular surface inflammation [17–19]. However, there was no significant difference between two groups in terms of conjunctival inflammation

(both groups have similar rates of moderate conjunctival inflammation) during the follow-up period in the current study.

Ocular pain originating from cornea or conjunctiva is another problem which limits the satisfaction of the patients following pterygium surgery. In a previous study, 60% of the patients suffered from significant pain following surgery [2]. Furthermore, Pastor-Vivas et al. have demonstrated that 58% of the patients in the immediate postoperative and 47% of the patients in the postoperative day 2 had moderate or severe pain [20]. Different managements have been used to reduce the pain following pterygium surgery. Topical anesthetic drops can be administered; however, they have short acting duration and repeated administrations are required. Furthermore, topical anesthetics are toxic to corneal epithelium and delay the corneal wound closure [21]. Wishaw et al. used peribulbar morphine and showed satisfactory results in controlling postsurgical pain within 24 h [2]. But, systemic side effects such as nausea and vomiting and prolonged stay in the hospital were shown as the drawbacks of the opioid use in the ocular surgery [22]. Topical NSAIDs have been used to decrease pain following ocular surface surgeries [5, 23]. They

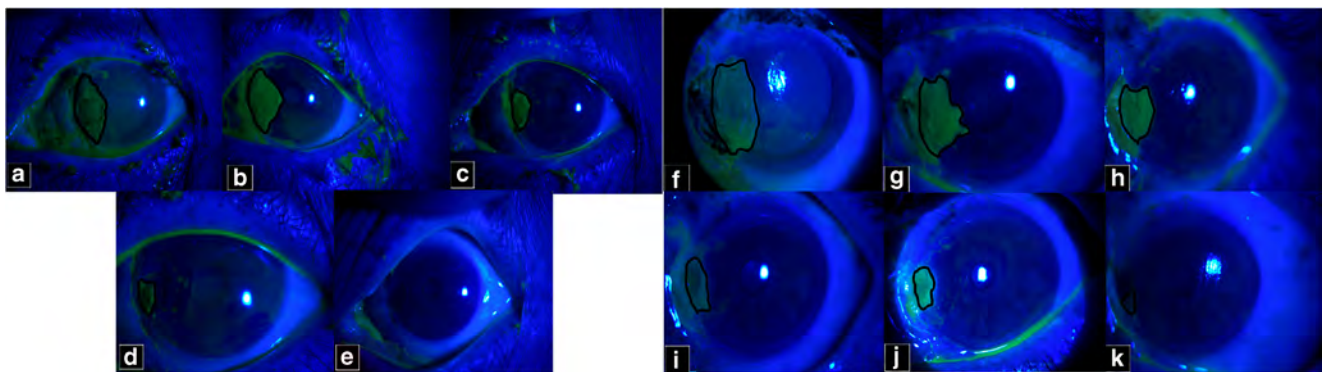


Fig. 1 Anterior segment colored photograph of the two patients who was applied 50% autologous serum drop (ASD) or conventional artificial tears (CAT). **a** Immediate postoperative period of the patient who received 50% ASD. Corneal defect area was marked and measured as 16.5 mm². **b** Postoperative day 1. Corneal epithelial defect area was 13 mm². **c** Postoperative day 2. Corneal epithelial defect area was 7 mm². **d** Postoperative day 3. Corneal epithelial defect area was 3 mm². **e** Postoperative day 4. Corneal epithelium was completely closed. **f**

Immediate postoperative period of the patient who received CAT. Corneal defect area was marked and measured as 17 mm². Corneal epithelium was completely closed at postoperative day 6. **g** Postoperative day 1. Corneal epithelial defect area was 11 mm². **h** Postoperative day 2. Corneal epithelial defect area was 7 mm². **i** Postoperative day 3. Corneal epithelial defect area was 5 mm². **j** Postoperative day 4. Corneal epithelial defect area was 4 mm². **k** Postoperative day 5. Corneal epithelial defect area was 1 mm²

have been found effective in reducing ocular pain; however, side effects such as superficial punctate keratitis, corneal infiltrates, and epithelial defects were reported [24]. Furthermore, corneal melting has been reported in eyes with dellen and tear film instability which may be encountered in patients with pterygium [24, 25]. Soft contact lenses have also been used to accelerate corneal re-epithelization and reduce ocular pain following pterygium excision [9]. Dağcıoğlu et al. have concluded that patients who were applied soft contact lenses maintained their daily activities following pterygium surgery. However, in eyes without epithelial barrier, soft contact lenses may lead to bacterial keratitis owing to bacterial contamination of the soft contact lenses which may be a potential limitation of this application [26].

ASD contains several components such as vitamin A, epidermal growth factor (EGF), fibronectin, and transforming growth factor- β (TGF- β) which are necessary for the proliferation, differentiation, and maturation of ocular surface epithelium [27–29]. Vitamin A is necessary for normal differentiation of squamous epithelium and prevents squamous metaplasia [30]. EGF and fibronectin support proliferation and migration of corneal epithelial cells [27, 31]. TGF- β is involved in epithelial cell migration and stromal repair process [32]. Substance P, NGF, and IGF-1 are neurotrophic factors that promote corneal epithelial wound healing [33, 34]. Additionally, serum contains anti-inflammatory cytokines such as interleukin (IL)-4, IL-10, and IL-1 receptor antagonist. IL-1 receptor antagonist has been shown to decrease signs of dry eyes in murine models [35]. Furthermore, ASDs are preservative free and its osmolality and biomechanical properties are similar to natural tears [36]. ASDs have been used in the treatment of various ocular surface disorders such as dry eye and dry eye-related disorders such as Sjögren syndrome, persistent epithelial defects, recurrent corneal erosion, and epithelial defects following surgery such as vitreoretinal or refractive surgery [8–11]. However, there is no study about the use of ASD following pterygium excision in the literature. In pterygium surgery, a corneal epithelial defect develops on and around the pterygium excision site. Faster corneal re-epithelization is important for corneal epithelial barrier development against bacterial infection as well as ocular pain that limits the patient satisfaction. In the current study, a prolonged corneal re-epithelization duration due to development of large corneal epithelial defects was the reason of 50% ASD concentration use. Although we cannot claim the superiority of 50% over 20% concentration of ASD (because we did not prepare 20% concentration and compare the outcomes), higher concentrations have been demonstrated to have better effect on corneal healing process that led us to use 50% concentration of ASD [37]. One-hundred-percent concentration could be preferred instead of 50% ASD to promote faster healing owing to higher concentrations of growth factors. However, 100% ASD might cause more ocular irritation than 50%

ASD due to alteration of tear osmolality and pH owing to higher serum protein concentration in patients who already have ocular irritation following surgery [37]. Furthermore, 100% ASD requires twice amount of blood to prepare the concentration and higher concentrations of TGF- β in 100% ASD might suppress corneal wound healing as reported previously [28]. Therefore, we preferred to use 50% concentration of ASD. Indeed, corneal re-epithelization was provided on 3 days in 84% of patients in ASD group. In CAT group, two thirds of the patients had complete corneal re-epithelization 5 and 6 days after surgery. The difference of mean corneal re-epithelization time between two groups was almost 2 days and seems to be clinically meaningful. Although we included the patients with no other systemic or local diseases, the difference of healing speed would be more in patients with diabetes or severe dry eye disease which may alter corneal epithelium healing [9, 38, 39]. Another benefit was seen on the VAS scores. In CAT group, patients suffered from moderate to severe pain (mean VAS score 7.1); however, in ASD group, patients have a moderate pain (mean VAS score 5.5) at postoperative day 1. Furthermore, ASD group had significantly lower VAS scores than CAT group in the remaining 4 days. Ocular pain originating from cornea or conjunctiva was thought as the result of surgical trauma, corneal epithelial defect, and suture irritation. Utilization of 50% ASD in the early postoperative period may have reduced ocular pain with faster corneal re-epithelization. Furthermore, lower pain scores may be related to anti-inflammatory cytokines such as interleukin 10 which has been shown to have somewhat analgesic effects in addition to anti-inflammatory effect [40]. In addition, although we did not estimate the viscosity of ASDs, ASDs may have yielded an extra soothing effect on suture irritation as stated by Jeng and Dupps [37].

ASD may have several adverse effects such as infection from contaminated drops, worsening of ocular inflammation, anemia from frequent blood draws, sticky sensation, allergic reaction, and self-resorbing subepithelial infiltrate [18]. However, we did not encounter any adverse effect due to ASD administration.

In conclusion, corneal epithelial defect and ocular pain are inevitable and disturbing results following pterygium surgery. ASDs seem to be a good alternative to other medications following pterygium surgery by accelerating corneal epithelium healing in addition to reduced postoperative ocular pain.

Compliance with ethical standards

Conflict of interest The authors declare that they have no conflict of interest.

Ethical approval All procedures performed in studies involving human participants were in accordance with the ethical standards of the institutional and/or national research committee and with the 1964 Helsinki declaration and its later amendments or comparable ethical standards.

Informed consent Informed consent was obtained from all individual participants included in the study.

References

- Akarsu C, Taner P, Ergin A (2003) Fluorouracil as chemoadjuvant for primary pterygium surgery preliminary report. *Cornea* 22(6):522–526
- Wishaw K, Billington D, O'Brien D, Davies P (2000) The use of orbital morphine for postoperative analgesia in pterygium surgery. *Anaesth Intensive Care* 28(1):43–45
- Brilakis HS, Deutsch TA (2000) Topical tetracaine with bandage soft contact lens pain control after photorefractive keratectomy. *J Refract Surg* 16(4):444–447
- Oksuz H, Tamer C (2006) Pain relief after pterygium surgery with viscous lidocain. *Ophthalmologica* 220(5):323–326
- Ozcimen M, Sakarya Y, Goktas S et al (2015) Effect of nepafenac eye drops on pain associated with pterygium surgery. *Eye Contact Lens* 41(3):187–189
- Shortt AJ, Allan BD, Evans JR (2013) Laser-assisted in-situ keratomileusis (LASIK) versus photorefractive keratectomy (PRK) for myopia Cochrane database. *Syst rev* 31(1):CD005135
- Daglioglu MC, Coşkun M, İlhan N et al (2014) The effects of soft contact lens use on cornea and patient's recovery after autograft pterygium surgery. *Cont Lens Anterior Eye* 37(3):175–177
- Tsubota K, Goto E, Fujita H et al (1999) Treatment of dry eye by autologous serum application in Sjogren's syndrome. *Br J Ophthalmol* 83(4):390–395
- Tsubota K, Goto E, Shimmura S et al (1989) Treatment of persistent corneal epithelial defect by autologous serum application. *Ophthalmology* 106(10):1984–1989
- Chen Y, Hu F, Huang J et al (2010) The effect of topical autologous serum on graft re-epithelialization after penetrating keratoplasty. *Am J Ophthalmol* 150(3):352–359
- Schulze D, Sekundo W, Kroll P (2006) Autologous serum for the treatment of corneal epithelial abrasions in diabetic patients undergoing vitrectomy. *Am J Ophthalmol* 142(2):207–211
- Hondur AM, Akcam T, Karaca EE, Yazici Eroglu H, Aydin B (2016) Autologous serum eye drops accelerate epithelial healing after LASEK. *Curr Eye Res* 41(1):15–19
- Barequet IS, Soriano ES, Green WR, O'Brien TP (1999) Provision of anaesthesia with a single application of lidocaine 2% gel. *J Cataract Refract Surg* 25:626–631
- Kheirkhah A, Casas V, Sheha H, Raju VK, Tseng SC (2008) Role of conjunctival inflammation in surgical outcome after amniotic membrane transplantation with or without fibrin glue for pterygium. *Cornea* 27(1):56–63
- Hirst LW (2003) The treatment of pterygium. *Surv Ophthalmol* 48(2):145–180
- Ang LP, Chua JL, Tan DT (2007) Current concepts and techniques in pterygium treatment. *Curr Opin Ophthalmol* 18(4):308–313
- Azari AA, Rapuano CJ (2015) Autologous serum eye drops for the treatment of ocular surface disease. *Eye Contact Lens* 41(3):133–140
- Welder JD, Bakhtiari P, Djalilian AR (2011) Limbitis secondary to autologous serum eye drops in a patient with atopic keratoconjunctivitis. *Case Rep Ophthalmol Med* 2011:576521
- Pflugfelder SC, Corrales RM, de Paiva CS (2013) T helper cytokines in dry eye disease. *Exp Eye Res* 117:118–125.19
- Pastor-Vivas AI, Alejandre-Alba N, García-Vega MI, Ariño-Gutiérrez M, García-Sandoval B, Jiménez-Alfaro I (2011) Quantifying and classifying postsurgical pain in pterygium surgery with conjunctival autografts. *Arch Soc Esp Oftalmol* 86(6):176–179
- Peyman GA, Rahimy MH, Fernandes ML (1994) Effects of morphine on corneal sensitivity and epithelial wound healing: implications for topical ophthalmic analgesia. *Br J Ophthalmol* 78(2):138–141
- Padda GS, Cruz OA, Krock JL (1997) Comparison of postoperative emesis, recovery profile and analgesia in pediatric strabismus repair. *Ophthalmology* 104(3):419–424
- Caldwell M, Reilly C (2008) Effects of topical nepafenac on corneal epithelial healing time and postoperative pain after PRK: a bilateral, prospective, randomized, masked trial. *J Refract Surg* 24(4):377–382
- Flach AJ (2000) Topically applied non-steroidal anti-inflammatory drugs and corneal problems: an interim review and comment. *Ophthalmology* 107(7):1224–1226
- Machkie IA (1971) Localized corneal drying in association with dellen, pterygia and related lesions. *Trans Ophthalmol Soc UK* 91:129–145
- Hondur A, Bilgihan K, Cirak MY, Dogan O, Erdinc A, Hasanreisoglu B (2008) Microbiologic study of soft contact lenses after laser subepithelial keratectomy for myopia. *Eye Contact Lens* 34(1):24–27
- Ohashi Y, Motokura M, Kinoshita Y, Mano T, Watanebe H, Kinoshita S et al (1989) Presence of epidermal growth factor in human tears. *Invest Ophthalmol Vis Sci* 30(8):1879–1882
- Gupta A, Monroy D, Ji Z, Yoshino K, Huang A, Pflugfelder SC (1996) Transforming growth factor beta-1 and beta-2 in human tear fluid. *Curr Eye Res* 15(6):605–614
- Nelson JD, Gordon JF (1992) Topical fibronectin in the treatment of keratoconjunctivitis sicca. Chiron Keratoconjunctivitis Sicca study group. *Am J Ophthalmol* 114(4):441–447
- Sommer A (1983) Effects of vitamin a deficiency on the ocular surface. *Ophthalmology* 90(6):592–600
- Nakamura M, Sato N, Chikama T, Hasegawa Y, Nishida T (1997) Fibronectin facilitates corneal epithelial wound healing in diabetic rats. *Exp Eye Res* 64(3):355–359
- Kokawa N, Sotozono C, Nishida K, Kinoshita S (1996) High total TGF- 2 levels in normal human tears. *Curr Eye Res* 15(3):41–343
- Kojima T, Higuchi A, Goto E, Matsumoto Y, Dogru M, Tsubota K (2008) Autologous serum eye drops for the treatment of dry eye diseases. *Cornea* 27(Suppl 1):25–30
- Lambiase A, Rama P, Bonini S, Caprioglio G, Aloe L (1998) Topical treatment with nerve growth factor for corneal neurotrophic ulcers. *N Engl J Med* 338(17):1174–1180
- Okanobo A, Chauhan SK, Dastjerdi MH, Kodati S, Dana R (2012) Efficacy of topical blockade of interleukin-1 in experimental dry eye disease. *Am J Ophthalmol* 154(1):63–71
- Liu L, Hartwig D, Harloff S, Herminghaus P, Wedel T, Geerling G (2005) An optimised protocol for the production of autologous serum eyedrops. *Graefes Arch Clin Exp Ophthalmol* 243(7):706–714
- Jeng BH, Dupps WJ (2009) Autologous serum 50% eyedrops in the treatment of persistent corneal epithelial defects. *Cornea* 28(10):1104–1108
- Schrader S, Wedel T, Moll R, Geerling G (2006) Combination of serum eye drops with hydrogel bandage contact lenses in the treatment of persistent epithelial defects. *Graefes Arch Clin Exp Ophthalmol* 244:1345–1349
- Chikama T, Wakuta M, Liu Y, Nishida T (2007) deviated mechanism of wound healing in diabetic corneas. *Cornea* 26:S75–S81
- Borghini SM, Pinho-Riberio FA, Zarpelon AC, Cunha TM, Alves-Filho SH, Ferreria SH et al (2015) Interleukin-10 limits intense acute swimming-induced muscle mechanical hyperalgesia in mice. *Exp Physiol* 100(5):531–544