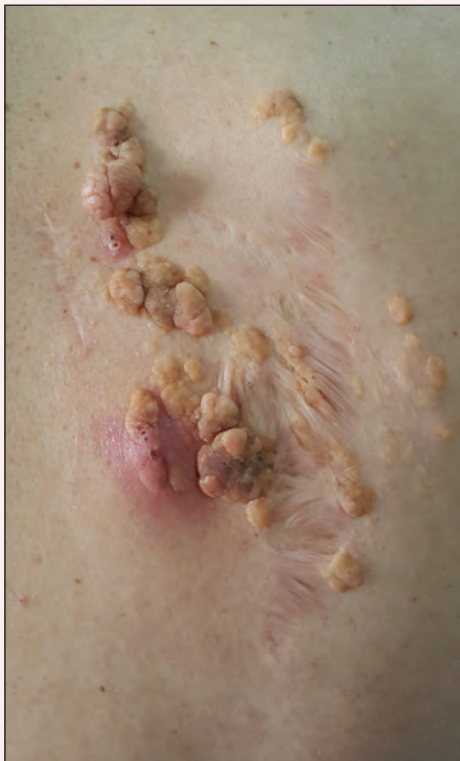

# Recurring Yellowish Papules and Plaques on the Back

Aslı Akın Belli, MD; Serkan Yaşar Çelik, MD



A 36-year-old man presented with a group of partially erythematous, yellowish papules and plaques ranging from 5 to 20 mm in diameter on the right side of the upper back of 20 years' duration. They were surgically excised 8 years prior but recurred and spread. The lesions occasionally were painful and tender with redness and discharge.

## What's the diagnosis?

- a. leiomyoma
- b. lymphangioma
- c. nevus lipomatosus cutaneus superficialis
- d. plexiform neurofibroma
- e. sebaceous nevus

Dr. Belli is from the Department of Dermatology, Muğla Sıtkı Koçman University Training and Research Hospital, Turkey. Dr. Çelik is from the Department of Pathology, Muğla Sıtkı Koçman University.

The authors report no conflict of interest.

Correspondence: Aslı Akın Belli, MD, Muğla Sıtkı Koçman University Training and Research Hospital, Department of Dermatology, Orhaniye Mah, İsmet Catak Cad, 48000 Muğla, Turkey (dr\_asliakin@hotmail.com).

## The Diagnosis: Nevus Lipomatosus Cutaneous Superficialis

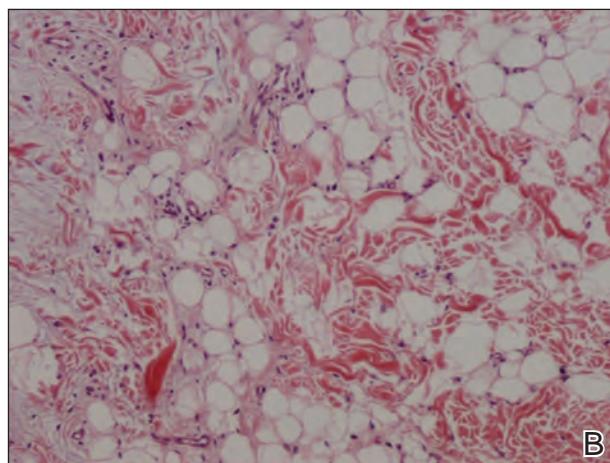
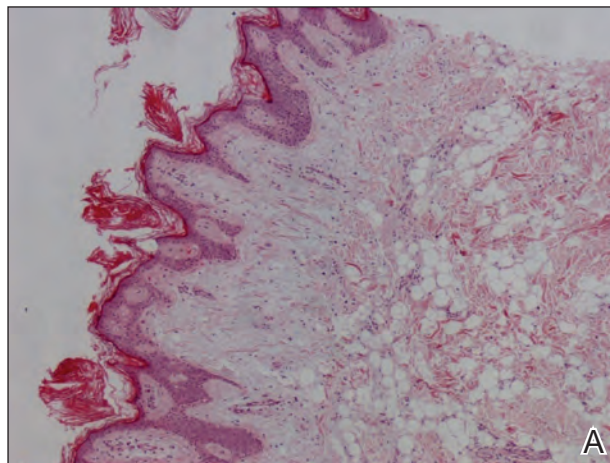
A punch biopsy was obtained from a skin lesion, which showed orthokeratosis, irregular acanthosis, papillomatosis, intense edema in the upper dermis, and mature fat lobules that dissected collagen fibers in the reticular dermis (Figure). Classical-type nevus lipomatosus cutaneous superficialis (NLCS) was diagnosed based on these clinical and histopathological findings. The patient was referred to the plastic surgery clinic for total excision of all lesions.

Nevus lipomatosus cutaneous superficialis is a rare hamartoma characterized by ectopic deposition of mature adipose tissue in the dermis.<sup>1</sup> It was first described by Hoffmann and Zurhelle<sup>2</sup> in 1921. Clinically, NLCS is classified into 2 subtypes: classical (multiple) and solitary. Classical-type NLCS is characterized by multiple pedunculated or sessile, soft, cerebriform, yellowish papules and nodules, especially in the pelvic area. Solitary-type NLCS presents as a sessile papule or nodule with no predilection for localization. Although the classical form of NLCS generally occurs in the first 2 decades of life, the solitary form usually appears in adulthood.<sup>3</sup> Nevus lipomatosus cutaneous superficialis has no gender predilection and there is no genetic or congenital defect association.<sup>1,4</sup>

The pathogenesis of NLCS still is unknown, but some theories have been proposed, such as the development of adipose metaplasia secondary to degeneration of connective tissue, the formation of a true nevus resulting from heterotopic development of adipose tissue, and the development of mature adipocytes from pericytes in dermal vessels.<sup>1,5</sup>

Histopathology of NLCS shows clusters of ectopic mature adipose tissue in varying rates (10%–50%) between collagen bundles in the dermis. Characteristically, there is no connection between the ectopic mature adipose tissue and the subcutaneous adipose tissue.<sup>3</sup> The differential diagnosis of NLCS includes neurofibroma, lymphangioma, sebaceous nevus, fibroepithelial polyps, leiomyoma, and lipomas.<sup>1,6</sup>

Treatment of NLCS generally involves basic surgical excision; however, patients treated with CO<sub>2</sub> laser also have been reported in the literature.<sup>5</sup> Because of the growth tendency and the large size of the classical form of NLCS, recurrence may occur, as in our case. In such cases, gradual surgical excision is recommended.<sup>5</sup> We present this case to indicate



Nevus lipomatosus cutaneous superficialis punch biopsy results revealed mature fat lobules in the superficial dermis, an increase in the number of vascular structures, and reduction of the skin appendages (A)(H&E, original magnification  $\times 100$ ). Mature adipose cells dissected collagen fibers in the reticular dermis (B)(H&E, original magnification  $\times 400$ ).

that undesirable surgical results or relapse may occur in untreated patients because of lesion growth and delayed diagnosis.

### REFERENCES

1. Goucha S, Khaled A, Zégloui F, et al. Nevus lipomatosus cutaneous superficialis: report of eight cases. *Dermatol Ther (Heidelb)*. 2011;1:25-30.

- Hoffmann E, Zurhelle E. Ubereinen nevus lipomatodes cutaneous superficialis der linkenglutaalgegend. *Arch Dermatol Syph.* 1921;130:327-333.
- Patil SB, Narchal S, Paricharak M, et al. Nevus lipomatosus cutaneous superficialis: a rare case report. *Iran J Med Sci.* 2014;39:304-307.
- Bancalari E, Martínez-Sánchez D, Tardío JC. Nevus lipomatosus superficialis with a folliculosebaceous component: report of 2 cases. *Patholog Res Int.* 2011;2011:105973.
- Kim YJ, Choi JH, Kim H, et al. Recurrence of nevus lipomatosus cutaneous superficialis after CO(2) laser treatment [published online November 14, 2012]. *Arch Plast Surg.* 2012;39:671-673.
- Wollina U. Photoletter to the editor - nevus lipomatosus superficialis (Hoffmann-Zurhelle). three new cases including one with ulceration and one with ipsilateral gluteal hypertrophy. *J Dermatol Case Rep.* 2013;7:71-73.