

Anatomical and clinical outcomes of vaginally assisted laparoscopic lateral suspension in comparison with laparoscopic lateral suspension

Eren Akbaba^{1,*}, Burak Sezgin¹, Ahmet Akin Sivaslioglu¹

¹Department of Obstetrics and Gynecology, Muğla Sıtkı Koçman University Faculty of Medicine, 48000 Muğla, Turkey

*Correspondence: erenakbaba@mu.edu.tr (Eren Akbaba)

DOI: [10.31083/j.ceog4804148](https://doi.org/10.31083/j.ceog4804148)

This is an open access article under the CC BY 4.0 license (<https://creativecommons.org/licenses/by/4.0/>).

Submitted: 2 May 2021 Revised: 12 June 2021 Accepted: 9 July 2021 Published: 15 August 2021

Background: In this retrospective study, we aimed to describe the surgical procedure for vaginally assisted laparoscopic lateral suspension (VALLS) and to compare its anatomical and clinical outcomes with laparoscopic lateral suspension (LLS). **Methods:** The surgical outcomes of 26 women with advanced-stage pelvic organ prolapse (POP) undergoing VALLS and 35 women with advanced-stage POP undergoing LLS were retrospectively analysed and compared. The surgical outcomes were documented according to the International Urogynecological Association guidelines. Complications were evaluated according to the Clavien-Dindo classification and classified using the joint project of the International Continence Society and the International Urogynecological Association Prosthesis/Graft Complication Classification System. **Results:** The results showed significant improvement in all POP Quantification measurements in both the VALLS and LLS groups, with overall objective cure rates of 88.4% and 80%, respectively (96.1% and 91.4%, respectively, for the apical compartment; 96.1% and 85.7%, respectively, for the anterior compartment). The median operation times for VALLS and LLS were 77 [66–90] minutes and 99 [82–125] minutes, respectively ($p = 0.001$). A significant improvement in POP symptoms was observed in both groups. Occult stress urinary incontinence (SUI) was detected in two (7.6%) VALLS patients, and de novo SUI developed in four (15.3%) VALLS patients post-operatively. Anterior compartment defects were detected in one VALLS and five LLS patients. Mesh erosion was found in one patient in each group. **Discussion:** VALLS appears to be an effective and reliable surgical method for patients with advanced-stage POP and can offer advantages in terms of operation time and POP recurrence rates.

Keywords

Laparoscopic lateral suspension; Minimally invasive surgery; Pelvic organ prolapse; POP surgery; Vaginally assisted laparoscopic lateral suspension

1. Introduction

Pelvic organ prolapse (POP) is the bulging of the uterus, anterior or posterior vaginal wall, or vaginal vault to a lower place or level [1]. The prevalence of POP in postmenopausal women is 3–6% according to symptoms and it may rise to 50% when based upon vaginal examination [2, 3]. A woman's lifetime operation risk of surgery for POP is 12–19%. Moreover, 10–30% of women with POP require reoperation [4].

Various vaginal and abdominal surgical management methods using native tissue or mesh have been developed to treat POP. Following the notification of the U.S. Food and Drug Administration in 2011 and 2019 regarding POP repair with a vaginal mesh, trans-abdominal mesh operations have gained popularity [5, 6]. Sacrocolpopexy (SCP) is the mostly preferred technique for treating POP laparoscopically. However, SCP involves a long operative time and a steep learning curve. The procedure includes sacral area dissection, which can be extremely difficult, particularly in overweight women, and may result in major neurological, ureteral, or vascular injuries [7, 8].

A dissection at the level of the promontory/sacral area is not necessary in the laparoscopic lateral suspension (LLS) procedure established by Dubuisson *et al.* [9]. Moreover, the risk of major complications appears to be lower than that of SCP. LLS can be performed using a T-shaped synthetic mesh graft and may or may not be a uterus-sparing procedure [10]. Studies on LLS have documented more than 90% objective success rate in the anterior and apical compartments after one year [11, 12]. Thus, LLS may be an alternative surgical option to SCP for the management of apical compartment defects in women with POP [13, 14]. The most critical step of the LLS procedure is the mesh placement in the vesicovaginal space. The true vesicovaginal space should be reached by performing dissection of a full vaginal wall layer. The mesh should be placed flat without folding or overstretching, and fixation should be performed using the appropriate suture technique and material which requires advanced laparoscopic surgical skills [15].

The aim of this study was to describe the surgical steps of a vaginally assisted laparoscopic lateral suspension (VALLS) procedure which enables quick and effortless suturation for the management of women with severe POP and to evaluate its effectiveness and reliability. To that end, we compared the preoperative characteristics and postoperative outcomes of patients undergoing VALLS and LLS.

2. Methods

2.1 Ethical approval

This was a retrospective study conducted in the Department of Obstetrics and Gynecology of the Faculty of Medicine of Muğla Sıtkı Koçman University, Turkey. The study was approved by the Clinical Investigations' Ethics Committee of Mugla University, Turkey (no. 4/I; 17 February 2021). The study was conducted in accordance with the provisions of the Declaration of Helsinki. Written informed consent was obtained from all patients before undergoing surgery.

2.2 Study design

The study included a study group of patients with stage 3–4 POP undergoing VALLS and a control group of patients with stage 3–4 POP undergoing LLS between February 2013 and March 2020. Patients with previous hysterectomy, SCP, or POP surgery with a vaginal mesh, patients older than 65 years, patients with diabetes, and patients with smoking habits were excluded. Transvaginal ultrasonography was performed in all patients before the operation. In addition, cervicovaginal smear scanning was performed in all patients. Urodynamic evaluation was done for the patients with pre- and post-operative urinary incontinence symptoms. According to the inclusion and exclusion criteria, 26 patients were included in the VALLS group, and 35 patients were included in the LLS group. The patients' demographic and clinical characteristics, prolapse-related symptoms, and operational information were obtained from the hospital's database and patient files. The physical examination results, reoperation and erosion rates, lower urinary tract symptoms (LUTS), and complications were retrieved.

All surgeries were performed by a single surgeon (EA). The patients were re-evaluated after a minimum of 12 months post-operatively. The pre- and post-operative examinations included Pelvic Organ Prolapse Quantification (POP-Q) measurements and staging. The degree of prolapse in points Ba, Bp, and C was determined according to the simplified POP-Q [1]. Urogynaecological examinations were performed with the patients in a semi-recumbent lithotomy position. The POP grade was evaluated by performing the Valsalva manoeuvre and/or coughing. The surgical outcomes were recorded according to the International Urogynaecological Association (IUGA) guidelines [16]. Satisfactory anatomic objective cure was defined as POP-Q sites Ba, C and Bp being less than -1 during follow-up. Complications were evaluated according to the Clavien-Dindo classification and classified using the joint project of the International Continence Society and the International Urogynecological Association Prosthesis/Graft Complication Classification System [17, 18].

2.3 Operation technique

2.3.1 Operation technique for VALLS

A T-shaped mesh with a rectangular part of 4×6 cm in the middle and two long arms of 2×18 cm was cut from

a 30×30 cm polypropylene macropore mesh (Parietene™, Covidien™, Trevoux, France) and prepared preoperatively. Surgery was performed under general anaesthesia in a lithotomy position. We used the four-port laparoscopic technique, a central 10-mm umbilical trocar for the 0-degree camera, two lateral ports, and a fourth ipsilateral port. A Foley catheter was inserted into the bladder, and a RUMI®II System (CooperSurgical, Trumbull, CT, USA) uterine retractor with a balloon tip was inserted into the uterine cavity for uterine manipulation and adequate exposure of the anterior and posterior vaginal fornices. The vesicovaginal space between the bladder and the anterior vaginal wall in the fascia plane was dissected until the lower third border of the vagina. The T-shaped mesh was placed in the abdominal cavity through a no.10 umbilical trocar. Combined with laparoscopic dissection, an approximately 4 cm circular incision was made vaginally 2 cm distal to the external cervical os to enter the vesicovaginal space and to reach the abdominal cavity. The middle part of the T-shaped mesh was placed in the vesicovaginal space and separately sutured vaginally with no. 2-0 Prolene® (monofilament polypropylene suture; Ethicon, Somerville, NJ, USA) suture to the anterior wall of the vagina, vesicovaginal fascia, pubocervical fascia, cervix, and isthmus of the uterus in such a way that there was no shrinkage in the mesh. The number of stitches was 10–14 sutures in all cases (Fig. 1).

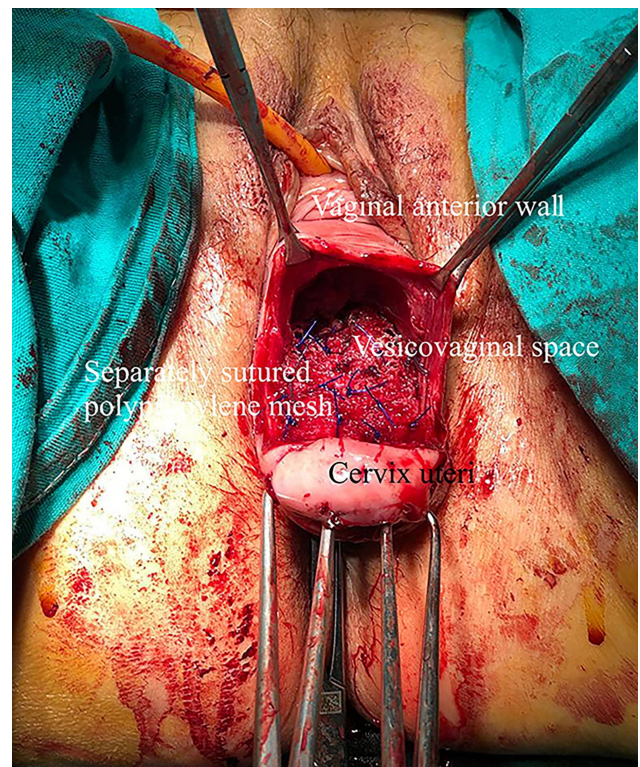


Fig. 1. The middle part of the T-shaped mesh with the dimensions of 4×6 cm is sutured to the vesico vaginal fascia with polypropylene suture material without wrinkling the mesh.

Table 1. Preoperative demographic features and findings.

Demographic features	VALLS n = 26	LLS n = 35	p-value
	Mean ± SD	Mean ± SD	
	Median [Min–Max]	Median [Min–Max]	
Age (year)	54.69 ± 7.58	55.69 ± 6.15	0.574*
BMI (kg/m ²)			0.311**
Normal weight: 18.5–24.9	14 (53.8)	19 (54.3)	
Overweight: 25–29.9	8 (30.8)	6 (17.1)	
Obese: ≥30	4 (15.4)	10 (28.6)	
Parity, (n)	3 [1–9]	3 [2–7]	0.511***
Number of vaginal deliveries	3 [1–8]	3 [2–7]	0.510***
Menopausal condition, n (%)			0.563**
Premenopausal	8 (30.8)	8 (22.9)	
Postmenopausal	18 (69.2)	27 (77.1)	
Previous POP surgery, n			0.356**
Colporrhaphy anterior	4	3	
Colporrhaphy posterior	2	3	
Manchester Fothergill	1	0	
Previous stress urinary incontinence operations, n			0.731****
Transobturator sub-urethral sling	1	0	
Tension free retropubic sling	2	2	
Kelly-Kennedy	2	3	
POP-Q			0.570**
Stage 3, n (%)	6 (23.1)	11 (31.4)	
Stage 4, n (%)	20 (76.9)	24 (68.6)	

Values expressed as the mean ± standard deviation, Median [Min–Max] or number (%). SD, standard deviation; BMI, body mass index; POP-Q, pelvic organ prolapse quantification. *Independent Samples *T* Test. **Chi Square Test. ***Mann Whitney U Test. ****Fisher's exact test.

The vaginal vault was closed vaginally with an absorbable no.0 Vicryl Rapide™ (polyglactin 910; Ethicon, Somerville, NJ, USA) suture. A 3-mm skin incision was made on both sides 2 cm above the iliac crest and 4 cm posterior to the anterior superior iliac spine. The forceps were initially advanced caudally in the retroperitoneal area, taking care to avoid the external iliac artery and vein, then advanced under the ligamentum rotundum. The distal tip of one long arms of the T shaped mesh was grasped and pulled out through the cutaneous incision. The lateral suspension procedure was performed in both sides. The lateral arms of the mesh were not fixed to the abdominal fascia, according to “tension free” repair principle. Peritonisation was also performed over the mesh inserted into the vesicovaginal space using a no. 2-0 absorbable Vicryl Rapide™ suture. The mesh was then cut at the skin level prior to the closure of the skin incision.

2.3.2 Operation technique for LLS

The only difference of LLS from VALLS was the mesh fixation to the vesicovaginal space. At this step no. 2-0 Prolene® was sutured intracorporeally with laparoscopy. As in the VALLS procedure, lateral arms of the mesh not sutured abdominal fascia in LLS procedure.

2.4 Statistical analysis

Statistical analysis was performed using IBM SPSS Statistics version 20.0 (IBM, Armonk, NY, USA) for Windows.

The Shapiro-Wilk test was used to evaluate data normality. The data were expressed as the median and range for continuous variables, and binary variables were reported as numbers and percentages. For inter-group comparisons, the independent samples *T*-test was used for parameters with a normal distribution and the Mann Whitney U Test was used for parameters with non-normal distribution. A Pearson's chi-square test or Fisher's exact test was used for comparison of categorical data. A *p* value of ≤0.05 was considered statistically significant.

3. Results

The demographic and preoperative clinical characteristics of the patients in the VALLS and LLS groups are summarised in Table 1. The preoperative characteristics of the two groups were similar.

The post-operative anatomical outcomes of the patients in the two groups are summarised in Table 2.

The median post-operative follow-up duration was 22 (13–30) months in the VALLS group and 32 (14–69) months in the LLS group (*p* = 0.09). A significant improvement in POP-Q scores was observed in all compartments, with overall objective cure rates of 88.4% in the VALLS group (96.1% in the apical compartment and 96.1% in the anterior compartment) and 80% in the LLS group (91.4% in the apical

Table 2. Anatomic outcomes in patients undergoing uterus preserving VALLS and LLS.

POP-Q	VALLS n = 26	LLS n = 35	p-value
	Median [25%–75%]	Median [25%–75%]	
Preop Point Ba	5 [3–6]	4 [3–4]	0.110
Preop Point C	6 [4–6]	6 [5–6]	0.982
Preop Point Bp	3 [2–3]	2 [2–3]	0.159
Postop Point Ba	-3 [(-3)–(-3)]	-2 [(-3)–(-2)]	0.001*
Postop Point C	-6 [(-7)–(-5)]	-5 [(-6)–(-3)]	0.087
Postop Point Bp	-2 [(-4)–(-1)]	-2 [(-3)–(-1)]	0.465

*Significant at ≤ 0.05 level; Mann Whitney U Test.

Table 3. Comparison of preoperative and postoperative lower urinary tract symptoms of patients who underwent VALLS and LLS.

Variables	Preop			Postop		
	VALLS n (%)	LLS n (%)	p-value	VALLS n (%)	LLS n (%)	p-value
Lower urinary tract symptoms						
Vaginal bulge	26 (100)	35 (100)	0.955	1 (3.8)	5 (14.3)	0.179
Urinary urgency	16 (61.5)	24 (68.6)	0.571	2 (7.7)	10 (28.6)	0.044*
Incomplete voiding	19 (73.1)	27 (77.1)	0.718	3 (11.5)	7 (20)	0.381
Urinary frequency	22 (84.6)	30 (85.7)	0.906	18 (69.2)	27 (77.1)	0.491
SUI	2 (7.7)	3 (8.6)	0.902	3 (11.5)	4 (11.4)	0.989
Constipation	9 (34.6)	11 (31.4)	0.795	2 (7.7)	2 (5.7)	0.761
Fecal Incontinence	4 (15.4)	4 (11.4)	0.653	2 (7.7)	2 (5.7)	0.760
Sexual activity	7 (26.9)	13 (37.1)	0.404	16 (61.5)	24 (68.6)	0.571
Dyspareunia	6 (23.1)	7 (20)	0.733	3 (11.5)	3 (8.6)	0.703
Pelvic pain	14 (53.8)	19 (54.2)	0.973	10 (38.4)	13 (42.8)	0.917

*Significant at ≤ 0.05 level; Chi Square Test. SUI, stress urinary incontinence.

Table 4. Postoperative complications.

Complications	VALLS n = 26	LLS n = 35	p-value
Recurrence, n (%)	3 (11.5)	7 (20)	0.494*
Apical compartment	1 (3.8)	3 (8.5)	
Anterior compartment	1 (3.8)	5 (14.2)	
Posterior compartment	1 (3.8)	2 (5.6)	
Repeat surgery for recurrence, n (%)	1 (3.8)	7 (17.1)	0.122*
Apical compartment	0	2 (5.6)	
Anterior compartment	1 (3.8)	4 (11.2)	
Posterior compartment	0	2 (5.6)	
Vaginal mesh erosion, n (%)	1 (3.8)	1 (2.8)	0.675*
Repeat surgery (Retropubic sling) for SUI, n (%)	4 (15.3)	5 (14.2)	0.591*

SUI, stress urinary incontinence. *Fisher's exact test.

compartment and 85.7% in the anterior compartment). In our study, we found the median operative time as 77 [66–90] minutes for VALLS, and 99 [82–125] minutes for LLS ($p < 0.001$).

The pre- and post-operative LUTS of the patients in the two groups are displayed in Table 3. In both groups, the most common symptoms were palpable vaginal swelling and consequent walking difficulty. Considerable improvement in vaginal bulging, urgency, incomplete voiding, urinary frequency, and difficulty in defecation was observed post-

operatively. In the VALLS group, occult stress urinary incontinence (SUI) was observed in two (7.6%) women, and de novo SUI developed in 4 (15.3%) women post-operatively. In the VALLS group, the rate of sexually active women increased from 7 (26.9%) to 16 (61.5%).

The post-operative complications in the two groups are shown in (Table 4). There were no major complications in either group (Clavien-Dindo grade 1). In one patient undergoing VALLS and two patients undergoing LLS, bladder perforation occurred during the dissection of the vesicovaginal

space, and suturing was performed intraoperatively. No patient required a blood transfusion or underwent laparotomy.

In terms of recurrence, an anterior compartment defect was observed in one patient in the VALLS group, and anterior colporrhaphy was performed. The patient had a BMI of 27 kg/m². In the LLS group, anterior compartment defects were observed in five patients, one of whom was overweight and four were obese. Concurrent apical and anterior compartment defects were observed in two patients in the LLS group.

Grade 2 (>1 cm) anterior vaginal wall mesh exposure occurred in one patient in each group, with similar mesh erosion characteristics. The exposed part was detected between two and six months post-operatively and categorised as 3BT3S1 according to the Prosthesis/Graft Complication Classification System. In these patients, the exposed mesh was partially excised, and the vaginal mucosa was primarily repaired.

4. Discussion

POP is a very common condition, especially in obese women. A restoration of the disrupted anatomical relationships to normal anatomy contributes to a regression of LUTS and may exert positive functional and psychological effects [19]. Although several vaginal, abdominal, and endoscopic surgical techniques have been developed for the treatment of advanced POP, the optimal approach has yet to be determined. This study aimed to describe the surgical steps of a VALLS procedure for the treatment of women with POP stage ≥ 3 and evaluate its effectiveness by comparing it with LLS. Our results showed that VALLS provided better rates of anatomical support, symptomatic relief, patient satisfaction, intraoperative and post-operative complications, and vaginal erosion. The apical compartment cure rate in patients undergoing VALLS was 96.1%, and the anterior compartment cure rate was 96.1% during a follow-up period of, on average, 22 months. These results are consistent with Russo *et al.* [20], who reported success rates of 94.1% in the apical compartment and 88.3% in the anterior compartment in robotic-assisted LLS. Ganatra *et al.* [21] who reviewed 11 retrospective studies with a mean follow-up of 24.6 months, found overall objective anatomical and subjective laparoscopic SCP success rates of 92% and 94.4%, respectively.

Laparoscopic suturing is not an easy task, especially in a deep and narrow area. Proper laparoscopic suturing of the mesh may account for a large part of the operation time. This procedure is particularly difficult and time-consuming in obese patients. Moreover, in advanced POP cases, suturing a large and long mesh without curling in the vesicovaginal area, including the pelvic fascia, may be possible only vaginally [22].

In our study, the median operation time was significantly shorter in the VALLS group than the LLS group. In a previous study with uterine sparing LLS, the mean operative time was reported as 189.26 (\pm 44.62) minutes [23]. In another

study with LLS, mean operative time was reported as 120 (63–280) minutes [11]. In these studies, concomitant surgeries were performed in addition to LLS, so their operation time was longer than ours. Moreover, VALLS may have shortened the total operative time by reducing the suturation time of the mesh to the anterior vaginal wall using laparoscopic access.

In this study, a significant amelioration of vaginal bulging, urinary urgency, incomplete voiding, and urinary frequency was observed in patients undergoing VALLS. An occult SUI rate of 20% has been reported in patients with a POP diagnosis, which is even higher in patients with advanced-stage POP [24]. Veit-Rubin *et al.* [14] reported a SUI rate of 6.6% after LLS. In this current study, de novo SUI was observed in four (15.3%) patients who underwent VALLS, and in five (14.2%) patients who underwent LLS group.

In the past, hysterectomy was often performed in POP patients [25]. Later, surgical repair without hysterectomy was preferred due to the belief that hysterectomy reduced libido and impaired sexual function. Uterus-sparing LLS is associated with higher satisfaction rates, better short-term subjective outcomes, and lower post-operative constipation and de novo SUI rates [23]. Avoiding hysterectomy may also offer anatomical and functional benefits, such as maintaining strong rectovaginal and vesicovaginal fascia and cervix support [26]. It can also reduce morbidity and complication rates. In relatively young and sexually active women, avoiding hysterectomy and disruption of the vaginal axis may be associated with better sexual function post-operatively [27].

Major causes of mesh-related complications, such as erosion/extrusion, include aggressive dissection, intensive catheterisation, poor suture techniques that disrupt the nutrition of the mesh site, improper mesh placement, and shrinkage of the mesh at the suture stage [28]. Traditional SCP and LLS use non-absorbable or delayed absorbable and monofilament sutures for mesh fixation to prevent detachment from the vagina and reduce the risk of erosion [29]. The inclusion of the pelvic fascia in the mesh suture, which is quite easy in VALLS, can further reduce the risk of erosion. In patients in whom the mesh is stitched vaginally in laparoscopic POP surgery, possible contamination of the mesh with the vaginal flora may increase the risk of mesh erosion. In contrast, studies evaluating cases of vaginally assisted SCP have found no increased risk of contamination caused by vaginal suturing of the mesh [20, 22]. Follow-up period may influence the results of the mesh erosion rates [30]. Previous studies have reported variable time intervals to exposure, ranging from 6 weeks to 8 years [14, 30, 31]. In a study related mesh erosion after abdominal sacrocolpopexy median time to erosion detection was 16.8 months [30], another study report that mesh erosion median time to diagnosis after laparoscopic lateral suspension was 20 months [32]. In the current study the median post-operative follow-up duration was 22 (13–30) months in the VALLS group and 32 (14–69) months in the LLS group. Although there was no statistically significant

difference between the two groups, the follow-up period of the patients who underwent LLS was longer.

In our study, mesh erosion in the anterior compartment was observed in only one (3.8%) of the 26 patients undergoing VALLS. This is slightly lower than previously reported rates. A systematic review found a 4% rate after abdominal surgery using mesh [30]. Another study reported a 4.3% rate after 417 LLS procedures [14].

One reason for recurrence after LLS is the separation of the mesh from the tissue due to a failure to suture tightly [33]. We encountered recurrence of anterior compartment defect in five patients in the LLS group and one patient in the VALLS group. These patients were overweight or obese. Only one (3.8%) patient in the VALLS group required reoperation after more than 12 months, which is consistent with previously reported reoperation rates (3.4–11%) [34].

LLS is not preferred if significant apical and posterior defects are present together [35]. In LLS procedures using T-shaped synthetic mesh grafts, the lateral mesh arms do not close the Douglas space [14]. This may result in the progression of the posterior vaginal compartment defect [36]. However, the suspension axis of a lateral mesh does not lead to enterocele or space of Douglas hernia in patients treated for apical and anterior POP [11]. Reduced reoperation and recurrence risks have been reported in patients undergoing apical compartment defect repair with simultaneous posterior compartment repair [37]. We repaired posterior compartment defects using posterior colporrhaphy. We had one case of rectocele recurrence in VALLS group.

Limitations of our study are its retrospective, single-centre design, small sample size, and short follow-up period. On the other hand, a strength of this study is that all operations were standardized and performed by the same surgeon. Our study contributes to the literature by describing a new surgical method. Prospective studies including large numbers of patients and longer post-operative follow-up periods are needed to further evaluate this approach and compare it with other pelvic reconstructive surgery techniques.

5. Conclusions

VALLS appears to be a reliable and efficient modified method for women with POP scheduled for LLS. VALLS may reduce the POP recurrence rates, especially in obese patients. It also offers an advantage in terms of operation time and can be helpful to surgeons with modest laparoscopic suturing abilities. Moreover, it provides the opportunity for pubocervical fascia plication and posterior colporrhaphy when necessary. Further studies are warranted to evaluate this technique.

Author contributions

EA conceptualized and designed the study, drafted the initial manuscript, performed surgical operations, and reviewed and revised the manuscript. BS and AAS designed the data collection instruments, collected data, carried out the initial

analyses, and reviewed and revised the manuscript. All authors read and approved the final manuscript.

Ethics approval and consent to participate

This study was conducted in the Department of Obstetrics and Gynecology of Muğla Sıtkı Koçman University Faculty of Medicine in retrospective design. The study was approved by the Clinical Investigations' Ethics Committee of Muğla University/Turkey (Approval date: February 17th, 2021 and No: 4/I). The written informed consent was obtained from all participants in accordance with Helsinki Declaration.

Acknowledgment

The authors wish to thank the numerous individuals who participated in this study. In addition, the authors thank all the peer reviewers for their opinions and suggestions.

Funding

This research received no external funding.

Conflict of interest

The authors declare no conflict of interest.

References

- [1] Haylen BT, de Ridder D, Freeman RM, Swift SE, Berghmans B, Lee J, *et al.* An international urogynecological association (IUGA)/international continence society (ICS) joint report on the terminology for female pelvic floor dysfunction. *Neurourology and Urodynamics*. 2010; 29: 4–20.
- [2] Nygaard I, Barber MD, Burgio KL, Kenton K, Meikle S, Schaffer J, *et al.* Prevalence of symptomatic pelvic floor disorders in women. *Journal of the American Medical Association*. 2008; 300: 1311–1316.
- [3] Barber MD, Maher C. Epidemiology and outcome assessment of pelvic organ prolapse. *International Urogynecology Journal*. 2013; 24: 1783–1790.
- [4] Smith FJ, Holman CDJ, Moorin RE, Tsokos N. Lifetime risk of undergoing surgery for pelvic organ prolapse. *Obstetrics and Gynecology*. 2010; 116: 1096–1100.
- [5] Food and Drug Administration. Urogynecologic surgical mesh. update on the safety and effectiveness of transvaginal placement for pelvic organ prolapse. 2011. Available at: <https://www.fda.gov/media/81123/download> (Accessed date: 15 April 2021).
- [6] Shoureshi PS, Lee W, Kobashi KC, Sajadi KP. Media coverage of the 2019 United States Food and Drug Administration ordered withdrawal of vaginal mesh products for pelvic organ prolapse. *International Urogynecology Journal*. 2021; 32: 375–379.
- [7] Vieillefosse S, Thubert T, Dache A, Hermieu J, Deffieux X. Satisfaction, quality of life and lumbar pain following laparoscopic sacrocolpopexy: suture vs. tackers. *European Journal of Obstetrics, Gynecology, and Reproductive Biology*. 2015; 187: 51–56.
- [8] Higgs PJ, Chua H, Smith ARB. Long term review of laparoscopic sacrocolpopexy. *BJOG: An International Journal of Obstetrics and Gynaecology*. 2005; 112: 1134–1138.
- [9] Dubuisson JB, Chapron C. Laparoscopic Iliac Colpo-Uterine Suspension for the Treatment of Genital Prolapse Using Two Meshes: a New Operative Laparoscopic Approach. *Journal of Gynecologic Surgery*. 1998; 14: 153–159.
- [10] Dubuisson J, Chapron C, Fauconnier A, Babaki-Fard K, Dendrinis S. Laparoscopic management of genital prolapse: lateral suspension with two meshes. *Gynaecological Endoscopy*. 2000; 9: 363–368.

- [11] Mereu L, Tateo S, D'Alterio MN, Russo E, Giannini A, Mannella P, *et al.* Laparoscopic lateral suspension with mesh for apical and anterior pelvic organ prolapse: a prospective double center study. *European Journal of Obstetrics & Gynecology and Reproductive Biology.* 2020; 244: 16–20.
- [12] Martinello R, Scutiero G, Stuto A, Indraco U, Cracco F, Borghi C, *et al.* Correction of pelvic organ prolapse by laparoscopic lateral suspension with mesh: a clinical series. *European Journal of Obstetrics & Gynecology and Reproductive Biology.* 2019; 240: 351–356.
- [13] Dubuisson J, Yaron M, Wenger J, Jacob S. Treatment of genital prolapse by laparoscopic lateral suspension using mesh: a series of 73 patients. *Journal of Minimally Invasive Gynecology.* 2008; 15: 49–55.
- [14] Veit-Rubin N, Dubuisson J, Gayet-Ageron A, Lange S, Eperon I, Dubuisson J. Patient satisfaction after laparoscopic lateral suspension with mesh for pelvic organ prolapse: outcome report of a continuous series of 417 patients. *International Urogynecology Journal.* 2017; 28: 1685–1693.
- [15] Ko KJ, Lee K. Current surgical management of pelvic organ prolapse: Strategies for the improvement of surgical outcomes. *Investigative and Clinical Urology.* 2019; 60: 413–424.
- [16] Toozs-Hobson P, Freeman R, Barber M, Maher C, Haylen B, Athanasiou S, *et al.* An International Urogynecological Association (IUGA)/International Continence Society (ICS) joint report on the terminology for reporting outcomes of surgical procedures for pelvic organ prolapse. *International Urogynecology Journal.* 2012; 23: 527–535.
- [17] Clavien PA, Barkun J, de Oliveira ML, Vauthey JN, Dindo D, Schulick RD, *et al.* The Clavien-Dindo Classification of Surgical Complications: five-year experience. *Annals of Surgery.* 2009; 250: 187–196.
- [18] Haylen BT, Freeman RM, Swift SE, Cosson M, Davila GW, Deprest J, *et al.* An International Urogynecological Association (IUGA)/International Continence Society (ICS) joint terminology and classification of the complications related directly to the insertion of prostheses (meshes, implants, tapes) & grafts in female pelvic floor surgery. *International Urogynecology Journal.* 2011; 22: 3–15.
- [19] Barber MD. Pelvic organ prolapse. *British Medical Journal.* 2016; 354: i3853.
- [20] Athanasiou S, Grigoriadis T, Chatzipapas I, Protopapas A, Antsaklis A. The vaginally assisted laparoscopic sacrocolpopexy: a pilot study. *International Urogynecology Journal.* 2013; 24: 839–845.
- [21] Ganatra AM, Rozet F, Sanchez-Salas R, Barret E, Galiano M, Cathelineau X, *et al.* The Current Status of Laparoscopic Sacrocolpopexy: a Review. *European Urology.* 2009; 55: 1089–1105.
- [22] Warner WB, Vora S, Hurtado EA, Welgoss JA, Horbach NS, von Pechmann WS. Effect of operative technique on mesh exposure in laparoscopic sacrocolpopexy. *Female Pelvic Medicine & Reconstructive Surgery.* 2012; 18: 113–117.
- [23] Veit-Rubin N, Dubuisson J, Constantin F, Lange S, Eperon I, Gomel V, *et al.* Uterus preservation is superior to hysterectomy when performing laparoscopic lateral suspension with mesh. *International Urogynecology Journal.* 2019; 30: 557–564.
- [24] Cohn JA, Smith AL. Management of Occult Urinary Incontinence with Prolapse Surgery. *Current Urology Reports.* 2019; 20: 23.
- [25] Wilcox LS, Koonin LM, Pokras R, Strauss LT, Xia Z, Peterson HB. Hysterectomy in the United States, 1988–1990. *Obstetrics and Gynecology.* 1994; 83: 549–555.
- [26] Arikian DC, Coskun A. Vaginal length and incidence of dyspareunia after total abdominal versus vaginal hysterectomy. *European Journal of Obstetrics, Gynecology, and Reproductive Biology.* 2011; 157: 120.
- [27] Pulatoğlu Ç, Yassa M, Turan G, Türkyılmaz D, Doğan O. Vaginal axis on MRI after laparoscopic lateral mesh suspension surgery: a controlled study. *International Urogynecology Journal.* 2020; 32: 851–858.
- [28] Dällenbach P. To mesh or not to mesh: a review of pelvic organ reconstructive surgery. *International Journal of Women's Health.* 2015; 7: 331–343.
- [29] Greenberg JA, Clark RM. Advances in suture material for obstetric and gynecologic surgery. *Reviews in Obstetrics & Gynecology.* 2009; 2: 146–158.
- [30] Dällenbach P, De Oliveira SS, Marras S, Boulvain M. Incidence and risk factors for mesh erosion after laparoscopic repair of pelvic organ prolapse by lateral suspension with mesh. *International Urogynecology Journal.* 2016; 27: 1347–1355.
- [31] Ginath S, Garely AD, Condrea A, Vardy MD. Mesh erosion following abdominal sacral colpopexy in the absence and presence of the cervical stump. *International Urogynecology Journal.* 2013; 24: 113–118.
- [32] Akyol A, Akca A, Ulker V, Gedikbasi A, Kublay A, Han A, *et al.* Additional surgical risk factors and patient characteristics for mesh erosion after abdominal sacrocolpopexy. *Journal of Obstetrics and Gynaecology Research.* 2014; 40: 1368–1374.
- [33] Baessler K, Stanton SL. Sacrocolpopexy for vault prolapse and rectocele: do concomitant Burch colposuspension and perineal mesh detachment affect the outcome? *American Journal of Obstetrics and Gynecology.* 2005; 192: 1067–1072.
- [34] Diwadkar GB, Barber MD, Feiner B, Maher C, Jelovsek JE. Complication and Reoperation Rates after Apical Vaginal Prolapse Surgical Repair: a systematic review. *Obstetrics & Gynecology.* 2009; 113: 367–373.
- [35] Neuman M, Lavy Y. Conservation of the prolapsed uterus is a valid option: medium term results of a prospective comparative study with the posterior intravaginal slingoplasty operation. *International Urogynecology Journal and Pelvic Floor Dysfunction.* 2007; 18: 889–893.
- [36] Dubuisson J, Eperon I, Dällenbach P, Dubuisson J. Laparoscopic repair of vaginal vault prolapse by lateral suspension with mesh. *Archives of Gynecology and Obstetrics.* 2013; 287: 307–312.
- [37] Szymczak P, Grzybowska ME, Wydra DG. Comparison of laparoscopic techniques for apical organ prolapse repair—a systematic review of the literature. *Neurourology and Urodynamics.* 2019; 38: 2031–2050.