

Wound healing effect of Anzer origin propolis specimens on rats' intestinal incision

Zülfükar Kadir SARITAŞ^{1,a,✉}, Musa KORKMAZ^{1,b}, Hasan Hüseyin DEMİREL^{2,c}, Aziz BÜLBÜL^{3,d},
Tuba Berra SARITAŞ^{4,e}, Fatma GÖRÜCÜ^{1,f}, Yusuf KOÇ^{1,g}

¹Afyon Kocatepe University, Faculty of Veterinary Medicine, Department of Surgery, Afyonkarahisar, Turkey; ²Afyon Kocatepe University, Bayat Laborant and Veterinary Health Division, Afyonkarahisar, Turkey; ³Muğla Sıtkı Koçman University, Milas Veterinary Faculty, Department of Physiology, Milas, Muğla, Turkey; ⁴Afyonkarahisar Health Sciences University, Faculty of Medicine, Department of Anesthesiology and Reanimation, Afyonkarahisar, Turkey.

^aORCID: 0000-0002-7659-6635; ^bORCID: 0000-0002-7646-0009; ^cORCID: 0000-0002-4795-2266;

^dORCID: 0000-0003-0995-3986; ^eORCID: 0000-0002-3206-6851; ^fORCID: 0000-0001-7630-0788;

^gORCID: 0000-0002-6342-5466

✉Corresponding Author: zksaritas@hotmail.com

Received date: 02.12.2020 - Accepted date: 30.04.2021

Abstract: This study was investigated the wound healing effect of Anzer origin propolis specimens on rats' experimental intestinal incisions. Thirty-four male Wistar albino rats have been divided into five groups, weighing 250-300 gr. Water solution of Anzer propolis (PW3 [n=6], PW7 [n=6]) or ethanolic solution of Anzer propolis (PE3 [n=6], PE7 [n=6]) were administered. Control groups (K3 [n=5], K7 [n=5]) received no treatment. The surgical procedure (day 0) consisted of a laparotomy under general anesthesia, during which the colon was incised and repaired with sutures. The Anzer propolis specimen diluted with physiologic saline was administered by gavage (100 mg/kg/day) for 3 and 7 days before and after surgery to PW3 and PW7 groups. Ethanol dissolved Anzer propolis was administered by gavage (100 mg/kg/day) for 3 and 7 days before and after surgery to PE3 and PE7. Experimental animals have been humanly euthanized on the 3rd and 7th days for biochemical and histopathological evaluations. Serum total oxidant status, total antioxidant status, interleukin-1, interleukin-6, tumor necrosis factor-alpha, myeloperoxidase, hydroxyproline and nitric oxide, levels were measured by ELISA. The incision line sampled to evaluate inflammatory cells, fibroblastic activity, neovascularization, and collagen level. The study indicates that the ethanolic Anzer propolis solution's oral administration has a beneficial effect on intestinal wound healing for seven days pre-and postoperatively (PE7).

Keywords: Anzer propolis, intestinal incision wound healing, rat, total antioxidant status, total oxidant status.

Anzer menşeli propolis örneklerinin sıçanların bağırsak kesisi üzerindeki yara iyileştirici etkisi

Özet: Bu çalışmada, Anzer menşeli propolis örneklerinin sıçanların deneysel bağırsak kesisi üzerindeki yara iyileştirici etkisinin araştırılması amaçlanmıştır. 250-300 gr ağırlığındaki toplam 34 erkek Wistar Albino sıçan beş gruba ayrıldı. Anzer propolis su solüsyonu (PW3 [n=6], PW7 [n=6]) ve Anzer propolisin etanolik solüsyonu (PE3 [n=6], PE7 [n=6]) uygulandı. Kontrol gruplarına (K3 [n=5], K7 [n=5]) tedavi uygulanmadı. Cerrahi prosedür (0. gün) genel anestezi altında laparotomi ile kolon enzize edildi ve dikiş uygulanarak kapatıldı. Fizyolojik tuzlu su ile seyreltilmiş Anzer propolis örneği PW3 ve PW7 gruplarına ameliyat öncesi ve sonrası 3 ve 7 gün süreyle gavaj (100 mg/kg/gün) ile uygulandı. Etanolde çözdürülmüş Anzer propolisi, PE3 ve PE7 gruplarına ameliyat öncesi ve sonrası 3 ve 7 gün sonda ile (100 mg /kg/gün) uygulandı. Deney hayvanlarına biyokimyasal ve histopatolojik değerlendirmeler için 3. ve 7. günlerde ötenazi yapılmıştır. Serum total oksidan seviye, total antioksidan seviye, interlökin-1, interlökin-6, tümör nekroz faktör-alfa, miyeloperoksidaz, hidroksiprolin ve nitrik oksit seviyeleri ELISA yöntemi ile ölçüldü. Enzasyon hattı, yangı hücreleri, fibroblastik aktivite, neovaskularizasyonu ve kollajen seviyesini değerlendirmek için örnekledi. Bu çalışma, etanolik Anzer propolis solüsyonunun oral uygulamasının, operasyon öncesi ve sonrası yedi gün boyunca bağırsak yara iyileşmesi üzerinde faydalı bir etkiye sahip olduğunu göstermektedir (PE7).

Anahtar sözcükler: Anzer propolis, bağırsak enzisyonu yara iyileşmesi, rat, total oksidan seviye, total antioksidan seviye.

Introduction

The wound healing process is similar in various tissues; however, it has some distinctive gastrointestinal tract features (21). Unlike skin wounds, smooth muscle cells and fibroblasts make collagen synthesis and tensile strength occur much faster in the intestine. Knowledge related to local and systemic factors affecting gastrointestinal anastomosis healing has increased; however, anastomotic leakage and separation are serious problems that occur at a high frequency and result in high mortality (2, 15). Propolis, a resinous enzymatic substance enriched by bees' salivary glands, is used to fill beehive walls, cracks, or voids (10). Most of the compounds in propolis can be identified, verified, and classified after the purification step (3, 6).

The composition of propolis varies by the vegetation, climate, season, and environmental condition of the area where it is collected. Still, it mainly consists of resin (50%), beeswax and fatty acids (30%), essential oils (10%), polyphenols and flavonoids (10%), pollen (5%), and vitamins and minerals (5%) (24).

Propolis has been shown to have antitumor (1), antioxidant (4), antibacterial (11), antiviral (34), antifungal (35), and anti-inflammatory properties; however, the effect of propolis on oxidative stress is not well-documented. Anzer propolis is a regional propolis specimen unique to the Eastern Black Sea Region of Turkey. This study investigated the wound-healing effect of Anzer propolis 'specimen in rats' intestinal incisions using histopathologic and biochemical techniques.

Materials and Methods

A total of 34 Wistar albino male rats weighing 250-300 g were used in the study. Rats were housed in standard cages with a 12 h light/dark cycle. The animals were fed ad libitum up to 2 hours before the study and allowed free access to water.

Anesthesia Protocol: General anesthesia was provided as a combination of 13 mg/kg Xylazine hydrochloride (Rompun, 50 ml Fl. 23.32 mg/ml, Bayer-Germany) and 87 mg/kg Ketamine hydrochloride (Alfa, 10% Ala-Phe, Izmir, Turkey) via intramuscularly.

Surgical Protocol: After carefully shaving the abdomen of the rats, the area was cleaned with Povidone-iodine. A laparotomy was performed under general anesthesia and sterile conditions. After reaching the descending colon, a longitudinal incision was made in the antimesenteric region and sutured with double bowel sutures of 6-0 Prolene. The anastomosis line was checked for leaks and once hemostasis was confirmed, the incision was repaired with 6-0 polyglactin 910 Vicryl suture. In all groups, the abdominal wall and outer skin were closed

with standard suture techniques. Postoperative wound care was performed following skin sutures and isofix bandaging. Gentamycine 4 mg/kg/day was administered IM for 5 days.

Anzer Propolis Extract Preparation: Commercially available Anzer Propolis Extract containing 95% propolis, 5% ethanol, from the Anzer province of the East Black Sea Region in Turkey was used in the study. The ethanol content of the Anzer Propolis Extract was removed by vaporization, at the degree of 78.4 C in a dry heat oven. The purified propolis was then grounded and homogenized into powder using a homogenizer. Prior the gastric gavaged to the animals, purified propolis (100 mg/kg body weight) was diluted with saline to make a total volume of 1 mL for the PE3 and PE7 groups,

Study Groups: A total of 34 male Wistar albino rats weighing 250-300 g were randomly divided into the following groups:

Group 1: Propolis water-based 3 (PW3, n=6): 100 mg/kg/day Anzer propolis was diluted in saline and administered by gastric gavage from day -3 before surgery and continued for 3 days postoperatively. On the third day, the rats were euthanized.

Group 2: Propolis water-based 7 (PW7, n=6): 100 mg/kg/day Anzer propolis was diluted in saline and administered by gastric gavage from day -7 before surgery and continued until postop day 7 at which time the rats were euthanized.

Group 3: Propolis ethanol-based 3 (PE3, n=6): 100 mg/kg/day Anzer propolis was diluted in ethanol and administered by gastric gavage from day -3 before surgery and continued until the 3rd postoperative day at which time the rats were euthanized.

Group 4: Propolis ethanol-based 7 (PE7, n=6): Anzer propolis diluted in ethanol was gastric gavaged at a dose of 100 mg/kg/day from day -7 before surgery and continued until the 7th postoperative day at which time the rats were euthanized.

Control groups: (K3, n=5) and (K7, n=5): Propolis was not administered to this group pre- or postoperatively. On day 0, a colon anastomosis was performed following general anesthesia and laparotomy. Rats were euthanized on the 3rd (K3) and 7th day (K7) postop.

In all cases at necropsy, a sample was taken from the anastomosis line for histopathological examination, and blood samples were collected by cardiac puncture for biochemical measurements.

Biochemical Measurements: Serum levels of total oxidant status (TOS), total antioxidant status (TAS), interleukin -1 (IL-1), interleukin -6 (IL-6), tumor necrosis factor alpha (TNF- α), myeloperoxidase (MPO),

hydroxyproline (HYP), nitric oxide (NO), and antioxidant activity were measured by commercial ELISA kits with an MVGt Lambda Scan 200 (Bio-Tek Instrument, Winooski, VT, USA). The following Biont kits were used: **TOS** (Rat Total Oxidant Status, Catalog No: YLA1392RA, China), **TAS** (Rat Total Antioxidant Status, Catalog No: YLA1389RA, China), **IL-1** (Rat IL-1, Catalog No: YLA0153RA, China), **IL-6** (Rat IL-6, Catalog No: YLA0031RA, China), **TNF- α** (Rat TNF- α , Catalog No: YLA0118RA, China), **MPO** (Rat MPO, Catalog No: YLA0046RA, China), and **HYP** (Rat HYP, 96 TEST, Catalog No: YLA0068RA, China).

Histopathological Examination: Colon samples were stored in 10% neutral buffered formaldehyde solution. After 48 hours, specimens were trimmed and placed into cassettes, passed through an alcohol and xylene series, and blocked in paraffin. Blocks were cut 4-5 microns thick with a microtome and made into slides.

Hematoxylin-eosin stained sections were examined under a light microscope and changes in the incision line were evaluated.

Statistical Analysis: The results were acquired by applying one-way ANOVA tests using the SPSS 16.0 Statistics package program. A Duncan test was applied to results with statistical differences and the data were expressed as mean \pm standard deviation. Statistical significance was accepted as $P < 0.05$.

Results

Histopathological evaluation is detailed in Table 1. Serum levels of NO, TAS, TOS, MPO, IL-1, IL-6, TNF- α , and HYP were measured by ELISA (Table 2).

Histopathological examination results of tissue sections from the anastomosis line and inflammatory cells, fibroblastic activity, neovascularization and collagen levels were evaluated (Figure 1).

Table 1. Effects of Propolis on Bowel Wound (Mean \pm Standard Deviation).

| Histopathological findings | | | | | |
|----------------------------|------------------------------|------------------------------|------------------------------|------------------------------|---------|
| Groups | Inflammatory cells | Fibroblastic activity | Neovascularization | Collagen | P value |
| K3 | 1.43 \pm 0.43 ^c | 1.27 \pm 0.52 ^b | 1.43 \pm 0.43 ^c | 1.27 \pm 0.52 ^c | 0.000 |
| K7 | 1.61 \pm 0.51 ^c | 1.62 \pm 0.49 ^b | 1.57 \pm 0.53 ^c | 1.21 \pm 0.26 ^c | 0.000 |
| PW3 | 3.05 \pm 0.37 ^b | 3.38 \pm 0.75 ^a | 3.07 \pm 0.38 ^b | 3.37 \pm 0.41 ^b | 0.000 |
| PW7 | 4.05 \pm 0.42 ^a | 3.55 \pm 0.83 ^a | 3.93 \pm 0.49 ^a | 3.55 \pm 0.54 ^b | 0.000 |
| PE3 | 3.75 \pm 0.53 ^a | 3.92 \pm 0.52 ^a | 3.62 \pm 0.53 ^a | 3.58 \pm 0.52 ^b | 0.000 |
| PE7 | 4.03 \pm 0.41 ^a | 3.87 \pm 0.51 ^a | 4.11 \pm 0.41 ^a | 4.26 \pm 0.52 ^a | 0.000 |

^{a, b, c}: Inflammatory cell, fibroblastic activity, neovascularization and collagen values bearing different letters in the same column are statistically significant ($P < 0.05$).

K: control, PW: Water-based propolis, PE: Ethanol-based propolis.

Table 2. Group Biochemical Parameters (Mean \pm Standard Deviation).

| | K3 | K7 | PW3 | PW7 | PE3 | PE7 | P |
|---------------|-------------------------------------|-------------------------------------|-------------------------------------|------------------------------------|-------------------------------------|-------------------------------------|-------|
| TOS | 5.5760 \pm .28574 ^a | 4.7060 \pm .10801 ^c | 5.2680 \pm .11097 ^{ab} | 4.8400 \pm .16211 ^{bc} | 5.3333 \pm .11618 ^a | 4.1567 \pm .09691 ^d | 0.000 |
| TAS | 12.1820 \pm .62056 ^b | 13.0720 \pm 1.15246 ^{ab} | 12.3480 \pm .48555 ^b | 14.0340 \pm 1.32785 ^b | 15.1167 \pm .60039 ^{ab} | 16.5869 \pm 1.11400 ^a | 0.015 |
| IL-1 | 18.2660 \pm 1.72875 | 19.3460 \pm .40078 | 20.1780 \pm 1.09896 | 19.5440 \pm .61191 | 18.5733 \pm .88499 | 17.4683 \pm 1.22009 | 0.538 |
| TNF- α | 53.6660 \pm 7.95570 | 47.9740 \pm 6.30029 | 52.6200 \pm 7.07548 | 38.8400 \pm 2.87064 | 48.1250 \pm 5.32121 | 55.6917 \pm 8.76147 | 0.574 |
| IL-6 | 38.5400 \pm 4.44505 ^{ab} | 21.4500 \pm 1.63133 ^c | 37.8620 \pm 2.68475 ^{ab} | 22.0588 \pm 1.98869 ^c | 45.9617 \pm 5.02943 ^a | 29.0517 \pm 3.63555 ^{bc} | 0.000 |
| MPO | 21.8840 \pm 1.23079 ^{ab} | 18.2920 \pm .63377 ^c | 23.2700 \pm 1.31721 ^a | 19.3680 \pm .93094 ^{bc} | 22.1117 \pm 1.70461 ^{ab} | 14.8417 \pm .59530 ^d | 0.000 |
| HYP | 271.8000 \pm 15.11092 | 285.6000 \pm 9.38936 | 289.2000 \pm 9.74372 | 297.8000 \pm 6.56049 | 302.5000 \pm 4.07226 | 317.6667 \pm 13.50473 | 0.071 |
| NO | 13.4200 \pm .49639 ^a | 11.8400 \pm .37497 ^a | 13.4400 \pm .20640 ^a | 12.0000 \pm .34785 ^{ab} | 12.0167 \pm .30705 ^{ab} | 10.7500 \pm 1.05822 ^b | 0.023 |

^{a, b, c}: Values with different letters in the same line are statistically significant ($P < 0.05$). K: Control, PW: Water-based propolis, PE: Ethanol-based propolis, TOS: total oxidant status, TAS: total antioxidant status, IL-1: interleukin -1, IL-6: interleukin -6, TNF- α : tumor necrosis factor alpha, MPO: myeloperoxidase, HYP: hydroxyproline, NO: nitric oxide.

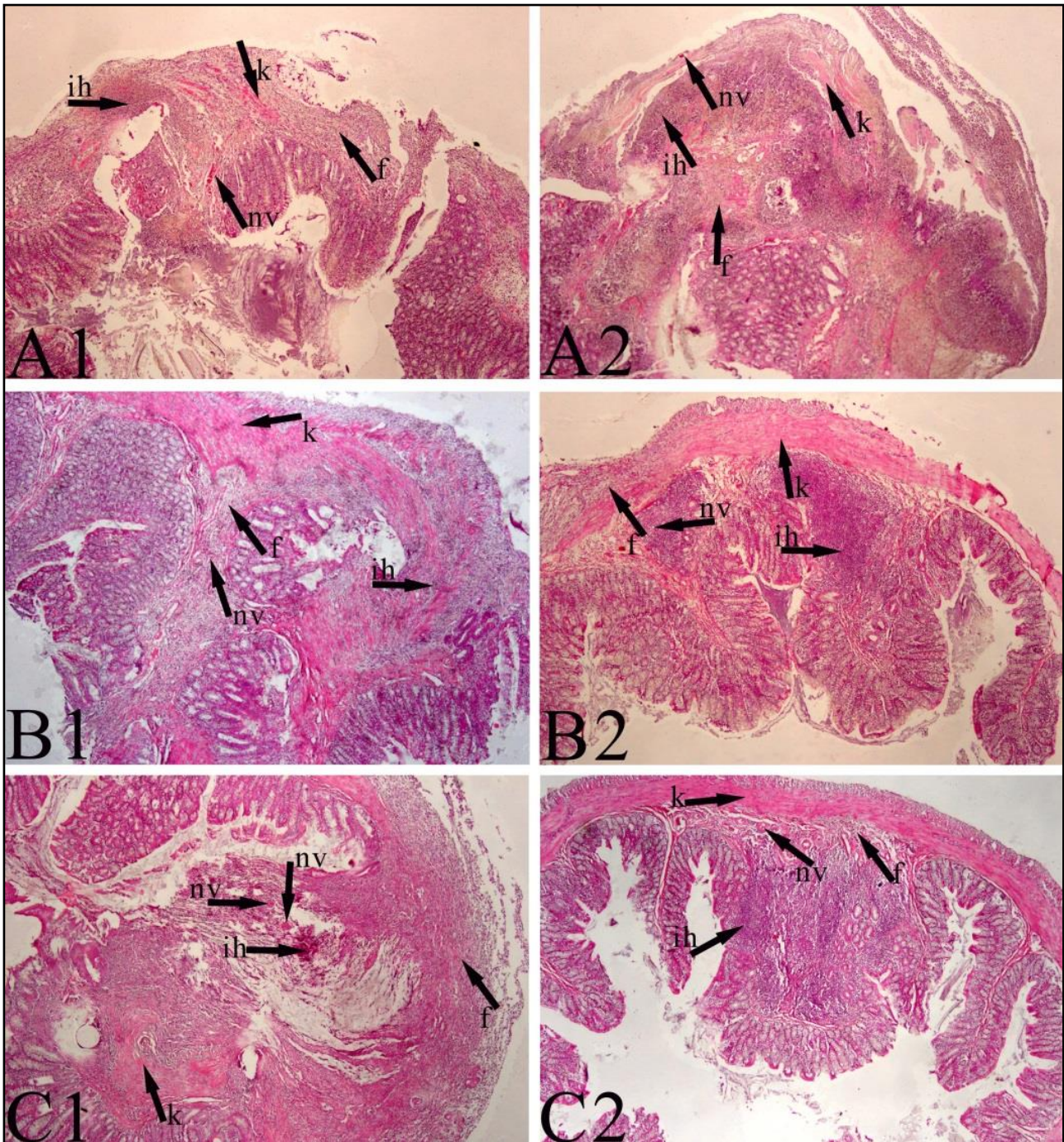


Figure 1. Histopathologic views of the groups.

A1:K3, A2:K7, B1:PW3, B2: PW7

C1: PE3, C2: PE7

K: Control, PW: Water-based propolis, PE: Ethanol-based propolis, nv: neovascularization, f: fibroblastic activity, ih: inflammatory cell, k: collagen.

When inflammatory cell measurement results and fibroblastic activity of all groups were compared, values for PW7, PE3, and PE7 groups were found to be statistically significantly higher than the other groups ($P<0.001$). The highest values for fibroblastic activity were determined in the PE3 and PE7 groups. Neovascularization measurements were highest in the PE7 and PW7 groups when compared to the other groups

($P<0.001$). The PE7 group had the highest arithmetic mean with statistical significance ($P<0.001$). The PE7 group was also statistically higher compared to the other groups with regard to collagen measurement ($P<0.001$) (Table 1).

There were no statistical differences between groups with regard to TNF- α values ($P>0.05$). The increase in IL-6 in the PE3 group was statistically significant when

compared to the other groups ($P < 0.001$). The PW7 group IL-6 value was the same as that measured in the K7 group ($P < 0.001$) (Table 2). NO, TOS, and TAS values in serum samples are detailed in Table 2.

The PE7 group TAS level was found to be higher than the other groups with a statistical significance ($P < 0.001$) while the TOS level was lower than all other groups ($P < 0.001$) (Table 2).

Discussion and Conclusion

While colon surgery is a common procedure, anastomosis leaks are a frequently encountered complication with high morbidity which has accelerated associated studies and research. This study aimed to histopathologically and biochemically evaluate the effects of orally dosed Anzer propolis on wound healing in rats following colon anastomoses.

Wound healing is a complex process in which the tissue repairs itself (23, 36). The wound healing process is similar in various tissues; however, it has some distinctive features in the gastrointestinal tract, for example, in bowel wounds, stretching time develops much earlier than for the skin (23) and collagen is synthesized by smooth muscle cells in intestinal wounds (23, 36).

Bowel wound healing includes inflammation, proliferation, fibroplasia, and maturation stages. Inflammation begins with vasodilation, secretion of vasoactive substances, increased vascular permeability, and neutrophil infiltration within 3 hours following vasoconstriction of the wound edges. Macrophages and fibroblasts then migrate to the wound area. Macrophages regulate inflammation by releasing cytokines (5, 16, 23).

In addition, systemic and local factors play a role in the healing of bowel wounds (13, 23). Important factors in the extracellular matrix are collagen fibers, fibroblasts, and immune cells that regulate wound strength in the early postoperative healing process (8, 13, 23).

Collagen fibrils synthesized in the submucosa form bridges in the anastomosis line. Even though in the early period the force that holds the wound edges together are the sutures, after 7-14 days they lose their importance with the increase of collagen bridges. In the maturation and restructuring phase, cross-links in collagen fibrils increase. At this stage, the wound becomes less cellular and granulation tissue is replaced by the tightening tissue (37).

Our findings obtained from the tissue sections taken from the suture line were compared statistically and PW7, PE3, and PE7 groups were found to be statistically higher than other groups. For fibroblastic activity PW7, PE3, and PE7 groups were statistically significantly higher than the other groups. The highest values were found in the PE3 and PE7 groups. For neovascularization measurement results, when the findings obtained in all groups were

compared statistically, PE7 and PW7 groups were the highest.

The PE7 group had the highest arithmetic mean with statistical significance. The PE7 group measurement was found to be statistically higher for collagen when compared to other groups. The quantitative measurement of HYP, an amino acid found only in collagen, is directly proportional to the formation of collagen, and its prediction aids in understanding the rate of progression in which the healing process occurs clinically. It is known that collagen accumulation is the sum of synthesis and destruction, and both occur simultaneously in the wound healing process (26).

While the HYP value was highest in the PE7 group serum samples, statistical significance between groups was not determined, although it was the lowest in the K3 group. The significantly high level of collagen in the PE7 group is supported by the literature.

A common complication in bowel operations is adhesion formation. It has been reported that in 12% to 17% of patients who have undergone abdominal surgery for various reasons, subileus occurs due to serosal adhesions developed in the early or late postoperative period (18, 20). In the current study, adhesion development was negligible at both the 3rd and 7th days.

MPO is an enzyme used in the creation of toxic agents that neutrophils use to break down the agents they phagocytize; thus, it is used as an indicator of neutrophil infiltration in tissues. Koç et al. (22) reported that MPO was significantly lower in a group in which 4% icodextrin was used following anastomoses. The low value detected indicated that less adhesions occurred due to a less severe inflammatory response (18).

In our study, the MPO level was found to be statistically significant in 3-day groups, while it was lowest in the PE7 group. In the study, adhesion development was evaluated according to the frequency (0-3+) at necropsy on the 3rd and 7th postoperative days. Adhesion development at a 0-1+ level was observed in all groups, but adhesion formation to the peritoneum and intra-abdominal organs was not observed at the anastomosis site. Our findings support the literature data.

It is reported that a complex reaction referred to as an acute phase inflammatory response begins immediately after surgical trauma (30) and the production of acute phase proteins increases immediately after surgical interventions (33). The acute phase protein response regulator is IL-6 (20, 32) which stimulates the secretion of other inflammatory cytokines such as TNF- α and IL-1 secretion of IL-6 (12, 20, 38).

Immunomodulatory effects have also been reported for honey proteins. MRJP-3 has been found to suppress IL-2, IL-4, and IFN- γ production by antigen-stimulated T cells (29). NO is produced by glycopeptides and

glycoproteins, zymosan-activated human neutrophils and murine macrophages, ranging from 2 to 450 kDa. NO is also produced by phagocytosis, LPS-activated murine macrophages, and TNF- α production by phagocytosis and human monocytic cells (25).

In this study, no statistical difference in serum TNF- α values was determined between groups. A rise in serum IL-6 levels in the PE3 group was statistically significant compared to other groups. The value in the PW7 group remained at the same level as that of the K7 group.

The level of IL-6 may have increased due to the effect of ethanol. It is also noteworthy that the PW7 IL-6 value, is approximately the same as that of the K7 group and shows that Anzer propolis dissolved in water causes less reaction. When the IL-1 serum results were compared statistically, there was no difference between groups.

Heinrich et al. (20) reported that the acute phase response peaked after trauma, and that mediators increased after surgery (9, 17, 28). Harada et al. (19) determined a statistically significant relationship between IL-6 and TNF- α levels. In light of these data, an increase of the parameters in the PW3 and PE3 groups was determined. This result was interpreted as proof that the level of inflammatory mediators decrease after day 3 in parallel with the literature.

Italian multifloral honey with daidzein, apigenin, genistin, luteolin, kaempferol, quercetin, and chrysin as major components has been reported to inhibit the release of LPS-stimulated N13 cells from microglia, (7). Given the role of neuroinflammation in neurodegenerative diseases, these data confirm the possible use of honey-flavonoid fraction against disorders such as Alzheimer's or Parkinson's.

Honey protein apalbumin-1, called MRJP-1, has been found to block the mannose receptors of human phagocytic cells, thereby inhibiting phagocytic activities. This inhibitory effect appears to be increased in honey containing methylglyoxal (MGO) due to apalbumin glycation (27).

Generally, phenolics are considered to contribute significantly to the antioxidant capacity of honey. Given that the phenolic composition of oral sources are highly variable, honey is expected to exhibit a wide variety of antioxidant properties (14, 31).

With regard to the TAS values, since the PE7 group was found to be higher than the other groups with a statistical significance it was considered evidence that Anzer propolis has an antioxidant effect. This finding supports the studies conducted with other propolis, honey, and honey derivatives. And considering that the PE7 group had the lowest level of TOS compared to the other groups, it is seen as evidence that the application of Anzer propolis shows considerable antioxidant activity.

We have confirmed with biochemical and histopathological findings that the oral administration of Anzer propolis dissolved in ethanol has positive effects on intestinal wound healing.

Financial Support

This study was supported by Afyon Kocatepe University Scientific Research Projects Committee (AKÜ BAPK 18.Kariyer.242) numbered project.

Ethical Statement

This study was approved by the Afyon Kocatepe University Animal Experiments Local Ethics Committee (11.06.2018 dated and AKUHADYK 93-18 numbered).

Conflict of Interest

The authors declare that there are no conflicts of interest.

References

1. **Ahn M-R, Kunimasa K, Ohta T, et al** (2007): *Suppression of tumor-induced angiogenesis by Brazilian propolis: major component artepillin C inhibits in vitro tube formation and endothelial cell proliferation*. Cancer Lett, **252**, 235-243.
2. **Akgün A, Kuru S, Uraldi C, et al** (2006): *Early effects of fibrin sealant on colonic anastomosis in rats: an experimental and case-control study*. Tech Coloproctol, **10**, 208.
3. **Alencar SMD, Oldoni TLC, Castro M, et al** (2007): *Chemical composition and biological activity of a new type of Brazilian propolis: red propolis*. J Ethnopharmacol, **113**, 278-283.
4. **Altuğ ME, Serarslan Y, Bal R, et al** (2008): *Caffeic acid phenethyl ester protects rabbit brains against permanent focal ischemia by antioxidant action: a biochemical and planimetric study*. Brain Res J, **1201**, 135-142.
5. **Braskén P** (1991): *Healing of experimental colon anastomosis*. Eur Surg Acta Chirurgica Supplement, **566**, 1-51.
6. **Campo Fernández M, Cuesta-Rubio O, Rosado Perez As, et al** (2008): *GC-MS determination of isoflavonoids in seven red Cuban propolis samples*. J Agric Food Chem, **56**, 9927-9932.
7. **Candiracci M, Piatti E, Dominguez-Barragán M, et al** (2012): *Anti-inflammatory activity of a honey flavonoid extract on lipopolysaccharide-activated N13 microglial cells*. J Agric Food Chem, **60**, 12304-12311.
8. **Carrico TJ, Mehrhof Jr AI, Cohen IK** (1984): *Biology of wound healing*. Surg Clin North Am, **64**, 721-733.
9. **Conner J, Eckersall P, Ferguson J, et al** (1988): *Acute phase response in the dog following surgical trauma*. Res Vet Sci, **45**, 107-110.
10. **Dimov V, Ivanovska N, Manolova N, et al** (1991): *Immunomodulatory action of propolis. Influence on anti-infectious protection and macrophage function*. Apidologie, **22**, 155-162.

11. **Drago L, De Vecchi E, Nicola L, et al** (2007): *In vitro antimicrobial activity of a novel propolis formulation (Actichelated propolis)*. J Appl Microbiol, **103**, 1914-1921.
12. **Ertel W, Faist E, Nestle C, et al** (1990): *Kinetics of interleukin-2 and interleukin-6 synthesis following major mechanical trauma*. J Surg Res, **48**, 622-628.
13. **Frostberg E, Ström P, Gerke O, et al** (2014): *Infliximab's influence on anastomotic strength and degree of inflammation in intestinal surgery in a rabbit model*. BMC Surg, **14**, 23.
14. **Gheldof N, Wang X-H, Engeseth NJ** (2002): *Identification and quantification of antioxidant components of honeys from various floral sources*. J Agric Food Chem, **50**, 5870-5877.
15. **Golub R, Golub RW, Cantu JR, et al** (1997): *A multivariate analysis of factors contributing to leakage of intestinal anastomoses*. J Am Coll Surg, **184**, 364-372.
16. **Graham MF, Drucker DE, Diegelmann RF, et al** (1987): *Collagen synthesis by human intestinal smooth muscle cells in culture*. Gastroenterology, **92**, 400-405.
17. **Gruys E, Toussaint M, Niewold T, et al** (2005): *Acute phase reaction and acute phase proteins*. J Zhejiang Univ Sci B, **6**, 1045-1056.
18. **Gümüş LT, Serinsöz E, Kanik EA, et al** (2013): *Karın içi adezyon önleyici % 4'lük ikodekstrin solüsyonunun gastrointestinal sistem anastomozları üzerine etkisi*. Ulus Travma Acil Cerr Derg, **19**, 305-312.
19. **Harada T, Yoshioka H, Yoshida S, et al** (1997): *Increased interleukin-6 levels in peritoneal fluid of infertile patients with active endometriosis*. Am J Obstet Gynecol, **176**, 593-597.
20. **Heinrich PC, Castell JV, Andus T** (1990): *Interleukin-6 and the acute phase response*. Biochem J, **265**, 621-636.
21. **Kılıçoğlu B, Kılıçoğlu S, Göçen V** (2005): *Gastrointestinal sistemde yara iyileşmesi*. SDÜ Tıp Fak Derg, **12**, 67-76.
22. **Koç O, Dağ A, Öcal AK, et al** (2013): *Karın içi adezyon önleyici %4'lük ikodekstrin solüsyonunun gastrointestinal sistem üzerine etkisi*. Ulus Travma Acil Cerr Derg, **19**, 305-312.
23. **Korkmaz M, Saritas T, Sevimli A, et al** (2015): *The effect of gabapentin and pregabalin on intestinal incision wound healing in rabbits*. Vet World, **8**, 279-283.
24. **Kurek-Górecka A, Rzepecka-Stojko A, Górecki M, et al** (2014): *Structure and antioxidant activity of polyphenols derived from propolis*. Molecules, **19**, 78-101.
25. **Mesaik MA, Dastagir N, Uddin N, et al** (2015): *Characterization of immunomodulatory activities of honey glycoproteins and glycopeptides*. J Agric Food Chem, **63**, 177-184.
26. **Minor R** (1980): *Collagen metabolism: a comparison of diseases of collagen and diseases affecting collagen*. Am J Pathol, **98**, 225-280.
27. **Molan PC, Rhodes T** (2015): *Honey: A biologic wound dressing*. Wounds, **27**, 141-151.
28. **Nishimoto N, Yoshizaki K, Tagoh H, et al** (1989): *Elevation of serum interleukin 6 prior to acute phase proteins on the inflammation by surgical operation*. J Clin Immunol, **50**, 399-401.
29. **Okamoto A, Hashimoto K, Neelson KH, et al** (2013): *Rate enhancement of bacterial extracellular electron transport involves bound flavin semiquinones*. Proc Natl Acad Sci, **110**, 7856-7861.
30. **Pepys MB** (1981): *C-reactive protein fifty years on*. The Lancet, **317**, 653-657.
31. **Petretto GL, Cossu M, Alamanni MC** (2015): *Phenolic content, antioxidant and physico-chemical properties of Sardinian monofloral honeys*. Int J Food Sci Tech, **50**, 482-491.
32. **Pullicino E, Carli F, Poole S, et al** (1990): *The relationship between the circulating concentrations of interleukin 6 (IL-6), tumor necrosis factor (TNF) and the acute phase response to elective surgery and accidental injury*. Lymphokine Res, **9**, 231-238.
33. **Roumen R, Van Meurs P, Kuypers H, et al** (1992): *Serum interleukin-6 and C reactive protein responses in patients after laparoscopic or conventional cholecystectomy*. Eur Surg Acta Chirurgica Supplement, **158**, 541-544.
34. **Shimizu T, Hino A, Tsutsumi A, et al** (2008): *Anti-influenza virus activity of propolis in vitro and its efficacy against influenza infection in mice*. Antivir Chem Chemother, **19**, 7-13.
35. **Silici S, Koç NA, Ayangil D, et al** (2005): *Antifungal activities of propolis collected by different races of honeybees against yeasts isolated from patients with superficial mycoses*. J Pharmacol Sci, **99**, 39-44.
36. **Stadelmann WK, Digenis AG, Tobin GR** (1998): *Physiology and healing dynamics of chronic cutaneous wounds*. Am J Surg, **176**, 26S-38S.
37. **Yağcı MA** (2011): *Ratlarda Curcumin'in Kolon Anastomozu İyileşmesi Üzerine Etkinliğinin Araştırılması*. Yüksek Lisans Tezi. Trakya Üniversitesi Sağlık Bilimleri Enstitüsü, Edirne.
38. **Yamamoto S, Shida T, Miyaji S, et al** (1993): *Changes in serum C-reactive protein levels in dogs with various disorders and surgical traumas*. Vet Res Commun, **17**, 85-93.